

Neurological physical examination

Dr. Norbert Kovács

version: 2023

Table of contents

Table of contents	2
Introduction	8
Physical examination	8
<u>Inspection</u>	<u>8</u>
<u>History taking (Recording of the anamnesis)</u>	<u>9</u>
<u>Palpation</u>	<u>9</u>
<u>Meningeal signs</u>	<u>9</u>
Nuchal rigidity.....	9
Kernig's sign.....	9
Brudzinski's sign.....	10
Interpretation of the meningeal signs.....	10
<u>Examination of cranial nerves</u>	<u>10</u>
The origin of cranial nerves	10
Localization of the lesions in the brainstem.....	11
<u>Examination of the olfactory nerve (I.)</u>	<u>11</u>
Examination of olfaction	12
Interpretation of the results.....	12
<u>Examination of the optic nerve (II.)</u>	<u>12</u>
Examination of vision	12
Interpretation of the results.....	13
Examination of the fundus	13
Interpretation of the results.....	13
Examination of the visual field	13
Interpretation of the results.....	13
Examination of reflexes	15
Pupillary reflex	15
Oculopalpebral reflex.....	15
<u>Examination of the oculomotor nerve (III.)</u>	<u>15</u>
Examination of the somatic motor functions.....	16
Ptosis.....	16
Position of the eye	16
Examination of the eye movements	16
Parasympathetic innervation	16
Pupillary reflex	16
Accommodation reflex.....	16
Convergence reflex	17
Causes of lesions of the oculomotor nerve.....	17
<u>Examination of the trochlear nerve (IV.)</u>	<u>17</u>
Position of the eye.....	17
Examination of the eye movements.....	17
Causes of lesions of the trochlear nerve	17
<u>Examination of the trigeminal nerve (V.)</u>	<u>18</u>
Examination of the somatosensory function	18
Interpretation of the somatosensory function.....	19
Examination of the motor function.....	19
Masseter reflex (jaw-jerk reflex)	19
Examination of superficial reflexes	19
Examination of the cornea reflex.....	19

<u>Examination of the abducens nerve (VI.)</u>	20
Position of the eye.....	20
Examination of the eye movements.....	20
Causes of lesions of the abducens nerve	20
<u>Examination of the facial nerve (VII.)</u>	20
Examination of the somatic motor function of the facial nerve	22
Examination of the sensory function of the facial nerve	23
Facial nerve reflexes	23
Corneal reflex.....	23
Oculopalpebral reflex, blink reflex	23
Stapedius reflex (or acoustic reflex).....	23
Localization of the level of the lesion in the case of peripheral facial palsy	24
<u>Examination of the vestibulocochlear nerve (VIII.)</u>	24
Examination of hearing	24
Rinne test.....	24
Weber's test.....	24
Interpretation of the results.....	24
Examination of the vestibular system	24
<u>Examination of the glossopharyngeal nerve (IX.)</u>	25
<u>Examination of the vagus nerve (X.)</u>	25
Examination of the uvula.....	25
Cough.....	25
Speech.....	25
Swallowing.....	25
Vocal cords.....	25
Pharyngeal reflex and soft palate reflex.....	26
<u>Examination of the accessory nerve (XI.)</u>	26
Examination of the trapezius muscle.....	26
Examination of the sternocleidomastoid muscle	26
Evaluation of the results	26
<u>Examination of the hypoglossal nerve (XII.)</u>	27
Examination of the tongue	27
Interpretation of the results.....	27
<u>Examination of the eye</u>	27
Examination of the eyelid.....	27
Examination of the pupil	28
Size of the pupil.....	28
Examination of the pupillary reflex.....	29
Examination of the convergence	29
Examination of the accommodation.....	29
<u>Examination of the eye movements</u>	30
Neural centers responsible for eye movements, gaze centers	30
Examination of the eye movements.....	30
The convergence of the eyes.....	30
Fixation	30
Directed eye movements	30
Tracking eye movements, smooth pursuit.....	30
Saccade.....	31
Diplopia.....	31
Gaze palsy	31
Nystagmus	31
Reflex eye movements	32
Oculocephalic reflex (doll's eyes phenomenon).....	32

Vestibuloocular reflex	32
Internuclear ophthalmoplegia (INO)	32
Useful videos related to the neurological examination of the eye and eye movements	32
<u>Vertigo and examination of the vestibular symptoms</u>	<u>33</u>
Characterization of the spontaneous and gaze-evoked nystagmus	33
Clinical methods for the examination of vestibular symptoms	34
Examination of the fixation	34
Examination of the optokinetic nystagmus	34
Dix-Hallpike maneuver (or Nysten–Bárány test)	34
Halmágyi head impulse test	34
Alternating cover test	35
HINTS, head impulse test, nystagmus, skew deviation test	35
Bárány test	35
Romberg test	35
Blind walking test	35
Unterberger test (also known as Fukuda test)	35
Tandem gait test (Heel-to-toe test)	36
Caloric testing	36
Interpretation of the results	36
Normal condition	36
Pathological nystagmus	36
Harmonic and disharmonic vestibular syndromes	36
Vestibular neuronitis	37
AICA infarction	37
PICA infarction	37
Superior cerebellar artery (SCA) infarction	37
Benign Paroxysmal Positional Vertigo (BPPV)	38
Useful videos related to the neurological examination of the vestibular system	38
<u>Examination of the motor system</u>	<u>38</u>
Muscle strength	38
Characterization of muscle strength	38
Examination of muscle weakness	39
Latent paresis tests	40
Tests to detect even minimal leg weakness	40
Muscle tone	41
Examination of muscle tone	41
Interpretation of the results	41
Phenomena reminding of increased muscle tone	42
Muscular trophy	42
<u>Reflexes</u>	<u>42</u>
Tendon reflexes (deep reflexes)	42
Radial reflex (brachioradial reflex)	43
Biceps reflex	44
Triceps reflex	44
Patella reflex	44
Achilles reflex	44
Superficial reflexes	45
Corneal reflex	45
Soft palate reflex	45
Pharyngeal reflex	45
Abdominal skin reflex	45
Plantar reflex	45
Cremaster reflex	46
Bulbocavernosus reflex (Osinski reflex)	46
Anal reflex	46
<u>Pathological reflexes</u>	<u>46</u>

	5.
Pyramidal signs.....	46
<i>Babinski's sign and triflexion response</i>	46
<i>Achilles clonus</i>	47
<i>Patella clonus</i>	47
<i>Hoffmann's sign</i>	47
<i>Trömner's sign</i>	47
Frontal release signs.....	47
<i>Grasp reflex</i>	48
<i>Rooting reflex</i>	48
<i>Bulldog reflex</i>	48
<i>Palmomental reflex</i>	48
<i>Glabellar reflex</i>	48
<i>Gegenhalten</i>	48
<u>Sensory system.....</u>	<u>48</u>
Examination of fine touch.....	49
Examination of vibration.....	50
Examination of the joint position sense.....	50
Directional scratch test.....	50
Examination of pain sensation.....	50
Examination of heat sensation.....	50
Examination of graphesthesia.....	51
Examination of two-point discrimination.....	51
Examination of simultaneous double stimuli.....	51
<u>Differentiation of central and peripheral lesions.....</u>	<u>51</u>
<u>Phenomenological characteristics of movement disorders.....</u>	<u>52</u>
Tremor.....	52
<i>Clinical picture</i>	52
<i>Most common disorders</i>	53
Parkinsonism.....	53
<i>The most commonly used methods for the examination of parkinsonism</i>	53
<i>Most common disorders</i>	54
Tic.....	54
<i>Clinical picture</i>	54
<i>Most common disorders</i>	55
Myoclonus.....	55
<i>Clinical picture</i>	55
<i>Most common disorders</i>	55
Dystonia.....	55
<i>Clinical picture</i>	55
Chorea and ballismus.....	56
<i>Most common disorders</i>	56
Athetosis.....	56
Ataxia.....	56
<u>Cerebellar symptoms.....</u>	<u>57</u>
Examination of the eye movements.....	57
<i>Fixation</i>	57
<i>Directed eye movements</i>	57
<i>Examination of saccade</i>	58
Vestibular symptoms.....	58
<i>Spontaneous nystagmus</i>	58
<i>Bárány test</i>	58
<i>Romberg test and sharpened Romberg test</i>	58
<i>Blind walking test</i>	58
<i>Tandem gait test (Heel-to-toe test)</i>	58
Examination of speech.....	58

	6.
Proprioceptive symptoms	58
Examination of ataxia	58
<i>Finger-to-nose test</i>	58
<i>Execution of quick alternating movements</i>	59
<i>Rebound test</i>	59
<i>Heel-to-knee-to-shin test</i>	59
<i>Examination of gait</i>	59
Interpretation of the results	59
<u>Gait abnormalities</u>	<u>60</u>
<i>Examination of gait</i>	60
<u>Examination of functions of the cortical lobe.....</u>	<u>61</u>
Apraxia.....	61
<i>Ideational apraxia</i>	61
<i>Ideomotor apraxia</i>	62
<i>Constructional apraxia</i>	62
<i>Gait apraxia</i>	62
Aphasia	62
<i>Broca's aphasia (motor aphasia)</i>	62
<i>Wernicke's aphasia (sensory aphasia)</i>	62
<i>Global or total aphasia</i>	62
<i>Anomic aphasia</i>	62
Agnosia	63
<i>Astereognosis (tactile agnosia)</i>	63
<i>Autotopagnosia</i>	63
<i>Prosopagnosia</i>	63
<i>Visual agnosia</i>	63
Anosognosia, neglect.....	63
Other gnostic disorders	63
<i>Agraphia</i>	63
<i>Alexia</i>	63
<i>Amusia</i>	63
<i>Acalculia</i>	63
<i>Gerstmann's Syndrome</i>	63
<u>Examination of a comatose patient</u>	<u>63</u>
Disorders of vigilance	64
<i>Torpidity, daze</i>	64
<i>Somnolence</i>	64
<i>Sopor</i>	64
<i>Coma</i>	64
<i>Brain death</i>	64
Integrative disorders of consciousness	64
<i>Tenebrosity</i>	64
<i>Confusion</i>	65
<i>Delirium</i>	65
<i>Persistent vegetative state</i>	65
<i>Minimally conscious state</i>	65
<i>Akinetic mutism</i>	65
<i>Locked-in syndrome</i>	65
Examination of a comatose patient.....	65
Glasgow Coma Scale (GCS)	66
<i>Best eye response (E - eye)</i>	67
<i>Best verbal response (V-verbal)</i>	67
<i>Best motor response (M-motor)</i>	67
<i>Interpretation</i>	67
Main causes of impaired consciousness	67
<u>Topical diagnosis</u>	<u>68</u>

Hemispheric damage	68
<i>Area of the middle cerebral artery (MCA)</i>	69
<i>Area of the anterior cerebral artery (ACA)</i>	69
<i>Area of the posterior cerebral artery (PCA)</i>	69
<i>Subcortical vs. cortical</i>	69
<i>Lacunar damage</i>	69
<i>Special cortical areas:</i>	70
<i>Watershed (border zone) infarcts</i>	70
Brainstem lesions	70
<i>Characteristics:</i>	70
<i>Alternating brainstem syndromes</i>	70
Cerebellar lesions	71
Spinal cord injury.....	71
<i>Dissociated sensory loss</i>	72
<i>Brown-Séquard's syndrome</i>	72
Conus lesion.....	72
Cauda lesion	72
Plexus lesions.....	73
<i>Cervical plexus</i>	73
<i>Brachial plexus</i>	73
<i>Lumbar plexus</i>	74
<i>Sacral plexus</i>	74
Root damage	74
<i>C₅ root lesion</i>	75
<i>C₆ root lesion</i>	75
<i>C₇ root lesion</i>	75
<i>C₈ root lesion</i>	75
<i>L₄ root lesion</i>	76
<i>L₅ root lesion</i>	76
<i>S₁ root-lesion</i>	76
<i>Maneuvers for the examination of root injuries</i>	77
Nerve lesion.....	78
<i>Median nerve</i>	78
<i>Ulnar nerve</i>	78
<i>Radial nerve</i>	78
<i>Peroneus profundus nerve</i>	78
Polyneuropathy (PNP)	79
Defect of the neuromuscular junction	79
Myopathy	80
The possible causes of paraparesis	80
<u><i>Example of a negative status</i></u>	<u>80</u>
References	80
Acknowledgment	80
Index	81

Introduction

In this booklet, we present the neurological physical examination and some special diagnostic methods of the nervous system. The majority of the experienced neurologists do not perform the complete physical examination, because a flexible examination can be planned based on the clinical questions, the anamnestic data, and the patient's complaints. In this booklet, we review the major steps of the neurological examinations, which can be important for both medical practitioners and medical students. There are plenty of diagnostic elements, which are important in specific topics, but they are rarely used in everyday practice. Here, we detail only those parts of these special procedures, which can be important from a clinical point of view.

The most important topics for medical students are highlighted with a yellow background.

Physical examination

The basic steps of a neurological physical examination:

- The recording of a thorough and detailed history
- Accurate identification and recording of the complaints
- How the complaints/problems have been developed? Are they acute, subacute, chronic, progressive, or paroxysmal?
- Setting up a working hypothesis: Where can be the impairment? In the central nervous system, in the peripheral nervous system, or both of them?
- Which structure can be impaired: the cerebrum, the brainstem, the spinal cord, a root, a plexus, a nerve, the neuromuscular junction, or a muscle?
- What can be the cause of the lesion: vascular, tumorous, infectious, inflammatory, neurodegenerative, metabolic, toxic, or functional cause?
- Does the physical examination confirm the hypothesis?
- Establishment of a differential diagnosis. To narrow down the possible diagnoses.
- What kind of instrumental and imaging techniques are necessary to confirm the hypothesis? Are they necessary at all?
- If the physical examination or the instrumental or imaging techniques do not confirm the hypothesis, search for an alternative hypothesis.
- To establish the final diagnosis.
- How severe is the disease?
- What kind of treatment is possible?
- What is the prognosis of the disease?

The neurological examination is usually unfamiliar to most patients. Therefore, we should properly inform the patient what we are going to do and what is expected of him to obtain good cooperation. It is also worth planning the examinations in a flexible and targeted manner for the patient's comfort. For example, if the patient is lying, first we should perform those examinations, which require lying position (e.g., meningeal signs, lower limb coordination tests).

Inspection

Similarly to the physical examination of internal medicine, the first and one of the most important steps of the neurological physical examination is the inspection. Just by looking at the patient, we may roughly assess his general condition. The color of the skin may refer to certain internal diseases (e.g., jaundice may refer to hepatic failure, cyanosis may refer to respiratory failure, or pale, sweating skin may refer to shock).

After a trauma or loss of consciousness, it is essential to look for external signs of injury and lateral tongue biting.

We should also observe the patient's movement pattern, which can be helpful in the more reliable assessment of subsequent muscle weakness. Observe the patient's gait. How quick it is? Is it a wide-based gait? Are there any signs of imbalance? Is the movement of the arms simultaneous? Observe the patient's mimic movements and speech as well.

History taking (Recording of the anamnesis)

The recording of the anamnesis includes the evaluation of previous disorders and treatments. In some cases, a heteroanamnesis is also necessary (e.g., in the case of epilepsy, dementia, sleep disorders, or aggravating, or dissimulating patients). Taking a family history is extremely important in the case of hereditary disorders. The development of certain diseases can be predicted based on social history (addiction, diet, living conditions).

In the case of fainting, unconsciousness, or epileptic seizures, several details can only be clarified by questioning both the patient and the witnesses of the problems:

- prodromal problems (e.g. fainting, sweating, aura symptoms),
- the duration of unconsciousness (e.g. a few seconds or a couple of minutes),
- amnesic problems related to the unconsciousness,
- abnormal phenomena (e.g. inability of following orders, tonic extensions of extremities, jerking movements, speech arrest, uncontrolled and purposeless movements, head injuries, enuresis, defecation, tongue biting, breathing problems, exclamations),
- the recovery of consciousness (e.g. fast within seconds or slowly within minutes, tenebrous state, agitation, feeling of muscle strain).

Palpation

Examination of the spinal column, palpation of the paravertebral muscles, and tapping the entire length of the spine are important in the cases of degenerative diseases of the spinal column and scoliosis. For example, in the case of dystonia palpation helps to identify the abnormally functioning muscle groups. The trophic properties (a.k.a. their quantity) of muscles can also be examined by palpation.

Meningeal signs

Nuchal rigidity

Examination of nuchal rigidity is not recommended for those patients, in whom cervical spinal injury and vertebral fracture or instability cannot be excluded. Otherwise, we may cause severe myelopathy.

Ask the patient to lie down and relax. Remove any pillows. Place your hands under the patient's head and lift it gently.

- Normally there is no resistance during lifting of the patient's head.
- In the positive case, there will be a sudden resistance during the bending of the patient's head forward and the patient reports pain.
- If the patient reports solely pain and the full range of motion without any resistance can be observed, the test is considered negative.
- If there is a steady stiffness during turning the patient's head right and left, we can speak about a stiff neck, which may develop in Parkinson's disease, dementia, or exsiccation as well.
- **Lhermitte's sign.** The sudden bending of the patient's head elicits an electrical sensation that runs down along the spine causing paraesthesia. It develops most commonly in multiple sclerosis, cervical tumor, and Arnold-Chiari malformation. It is also not considered to be a meningeal sign.

Kernig's sign

It can be examined by two different methods:

- The patient is lying, the hip and the knee joints are bent, while the patient's sole is on the examination table. Examine the two legs separately. Extend one of the patient's legs while the hip remains bent. The test is considered to be positive if there is resistance to extend the knee and non-radicular pain elicited by stretching of the leg is similar in both sides.
- Kernig's sign can be examined similarly to Lasègue's sign. The patient is lying horizontally on his back on the examination table with a straight hip and knees. Lift the patient's legs with straight knees separately. If the patient reports non-radicular pain and bends his knee to a certain degree, the test is considered to be positive. Compared to this, in the case of Lasègue's sign, the pain is radicular and appears on one side in most cases.

Brudzinski's sign

The patient is lying horizontally on his back on the examination table. Bending the patient's head forward is accompanied by flexion of the knees and the hip.

Interpretation of the meningeal signs

The presence of meningeal signs is usually considered to be caused by meningitis. Even in microbiologically proven infections, the meningeal signs may remain negative in meningitis with low leucocyte cell count in liquor or the case of immunodeficient patients. Consequently, meningitis can be present without positive meningeal signs. Therefore, if meningitis is clinically suspected, the liquor examination must be performed. Meningeal signs are not specific for meningitis, they can also be positive in the following conditions:

- subarachnoid hemorrhage
- liquor hypotension (e.g., after liquor puncture)
- tonsillar herniation
- cervical cancer or metastasis
- meningism (systemic infection, but without CNS involvement)



Meningeal signs: <https://www.youtube.com/watch?v=qXrp1-1gSQ0>

Examination of cranial nerves

The origin of cranial nerves

- Cranial nerves I and II are not considered to be true cranial nerves, because they do not emerge from the brainstem.
- Cranial nerves III and IV emerge from the mesencephalon.
- Cranial nerves V-VIII emerge from the pons.
- Cranial nerves IX-XII emerge from the medulla oblongata.

There are purely sensory (I, II, VIII), purely motor (III, IV, VI, XI, XII), and both sensory and motor (i.e. mixed) (V, VII, IX, X) cranial nerves.

Parasympathetic fibers emerge from the brainstem (III, VII, IX, and X). The sympathetic fibers are of spinal origin, and pass through the carotid system and reach the different parts of the brain via the wall of the arteries.

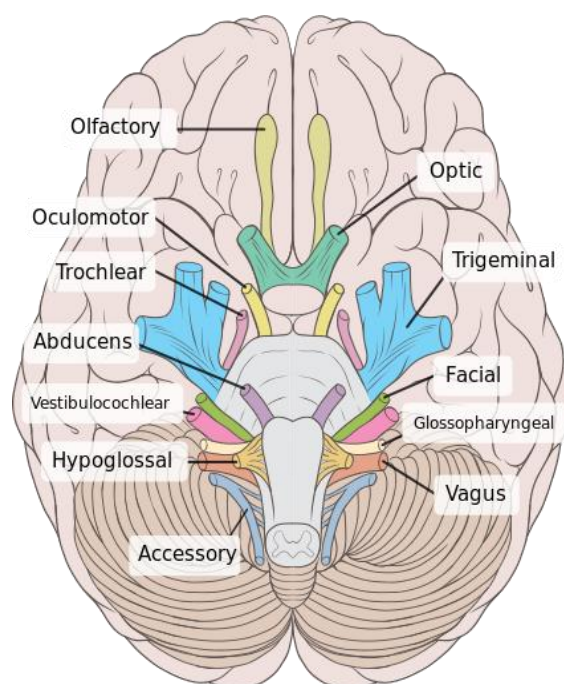


Figure 1. The origin of cranial nerves. Source: Wikipedia.org

Localization of the lesions in the brainstem

- **Lower motor neuron lesion, peripheral lesion** = Lesion of the motoric nucleus of the cranial nerves, or their axons, the neuromuscular junction, or the muscles supplied by the cranial nerves.
- **A central lesion or supranuclear lesion** = Lesion of the structures above the motor nucleus of a cranial nerve.
- Lesions in the brainstem (e.g., lacunar stroke, cavernoma, small tumors) can also lead to peripheral lesions if they affect the nucleus of a motor neuron (**nuclear lesion**). Therefore, lesions with certain localization of the brainstem (so within the area of the central nervous system) may result in a clinical picture resembling the symptoms of a peripheral lesion, if they affect the motor nucleus of the affected cranial nerve as well.
- A spinal lesion cannot lead to cranial nerve injury, i.e. if there is cranial nerve damage, the lesion should be in the cerebrum, the brainstem, a cranial nerve, or a neuromuscular junction, or it may emerge from the cerebellum affecting the surrounding structures as well.
- Unilateral cranial nerve impairment and a motor or sensory lesion affecting the **IPSILATERAL** limbs may usually refer to a supranuclear lesion.
- A unilateral cranial nerve injury and a motor or sensory lesion affecting the **CONTRALATERAL** limbs may usually refer to a lesion of the brainstem (**alternating brainstem syndromes or hemiplegia alternans**).
- A unilateral lesion of the cranial nerves V, VI, VII, and VIII, and a motor or sensory lesion affecting the **CONTRALATERAL** limbs may refer to lesions of the pons or the cerebellopontine angle.
- A unilateral lesion of the cranial nerves IX, X, and XI **WITHOUT** any motor or sensory lesions of **CONTRALATERAL** limbs may refer to a unilateral jugular foramen lesion (e.g., thrombosis, tumor).
- A unilateral lesion of the cranial nerves III, IV, V₁₋₂, and VI **WITHOUT** any motor or sensory lesions of the limbs may refer to a unilateral cavernous sinus lesion (e.g., thrombosis, tumor, and inflammation).

Examination of the olfactory nerve (I.)

The olfactory nerve is not considered to be a real cranial nerve, because it does not emerge from the brainstem. Its function is olfaction. Because the structures of the central nervous system involved in olfaction

receive information from both sides, the unilateral lesion of the fila olfactoria usually does not cause any noticeable problems for the patient.

A significant amount of the patients do not recognize olfactory dysfunction. It is important to ask properly that patients will be able to easily recognize the deficiency (e.g., Can you feel the smell of goulash?).

Examination of olfaction

Olfaction is rarely examined physically. Both sides should be examined separately. Ask the patient to close his eyes and occlude one of his nostrils. Place a pot containing volatile compounds under the other nostril, and ask the patient to breathe in. The patient should assess, whether he recognizes a smell (primary perception), and what kind of smell it is (cognitive function).

Use such kind of fragrances (e.g., vanilla, cinnamon, coffee, or orange), which do not irritate, because irritants (e.g., ammonia) stimulate not only the olfactory nerve but also the trigeminal nerve resulting in pain. If the suspicion arises that the patient is simulating, we can use empty vials or irritants as well.

- **Hyposmia.** The reduced ability to perceive odor.
- **Anosmia.** The inability to perceive odor.
- **Parosmia.** The perception of unpleasant odors and odors which are not present. It can develop e.g., in the case of migrainous aura and temporal lobe epilepsy.

Interpretation of the results

- Most commonly there are rhinogenic causes (e.g., rhinitis, nasal or sinus procedures, and inflammation, e.g. coronavirus infection) in the background of hyposmia.
- Head injury, nasal injury (lesion of the fila olfactoria or lesion of the olfactory bulb at the skull base).
- Even early phases of neurodegenerative diseases (e.g. Parkinson's disease, Alzheimer's disease) usually result in hyposmia.
- Olfactory meningioma

Examination of the optic nerve (II.)

The optic nerve is not a real cranial nerve, because it does not emerge from the brainstem. Its basic function is to transmit visual stimuli. The visual pathway: rods and cones (1st neuron) → bipolar cells (2nd neuron) → ganglion cells (3rd neuron) → optic nerve → optic chiasm → optic tract → lateral geniculate nucleus (4th neuron) → optic radiation → visual cortex (Brodmann area 17).

Examination of vision

- Before the examination always ask the patient, whether he has glasses. If he does, he should wear it during the examination. To identify exactly the value of the vision you can use a visual acuity board. Ask the patient to cover one of his eyes and read the numbers on the table from a 5 m distance. Thus you can express the value of vision in exact numbers. Subsequently, examine the other eye.
- When examined at the bedside, it is often enough to ask the patient to say how many fingers you are holding up from a 5 m distance. If the patient is unable to perform this task, repeat it from a shorter distance. In this case, examine how many meters are enough for the patient to be able to read the fingers you are holding up (e.g., the patient can count fingers at 1 meter). If it is unsuccessful, examine whether he can recognize movements directly in front of his eyes. If it is still unsuccessful, examine whether he can recognize the light.
- It is also suitable for exploratory testing, if you give a paper with some text to the patient, and ask him to read the letters.
- Use Ishihara books to examine the color vision.
- In the case of simulating or non-cooperative patient, the examination of the optokinetic nystagmus or the use of flash VEP (Flash visually evoked potentials) may be helpful to identify psychogenic blindness.

Interpretation of the results

- If you observe decreased visual acuity, its cause always has to be identified (ophthalmological vs. neurological).
- In the acute phase of papilloedema, the visual acuity may remain good. A decrease in visual acuity usually develops only in chronic papilloedema.

Examination of the fundus

The examination of the fundus should be performed in a darkened room. Sit or stand in front of the patient. If you examine the right eye, hold the ophthalmoscope in your right hand, and if you examine the left eye, hold the ophthalmoscope in your left hand. Ask the patient to look ahead to a point on the wall, and look into the pupil from an angle about 15 degrees. Try to find the optic disc, and examine the sharpness of its edge, the color (pale or not), and whether it is indented or not. Examine the retina, whether there are any vascular changes or hemorrhage. Retinitis pigmentosa may develop in certain movement disorders and storage diseases.

From neurological perspectives, the examination of fundus may be important before lumbar puncture, acute or subacute worsening of vision, or in the suspicion of increased intracranial pressure or retrobulbar neuritis. However, novel neuroimaging techniques decreased the importance of fundus exam in some cases.

Interpretation of the results

- If the disc has normal color and sharp edge, but the patient cannot see, it may refer to **retrobulbar neuritis**. It is usually unilateral.
- If the disc has a blurred edge and the patient cannot see well, it may refer to **optic nerve neuritis** or **papillitis**. Usually, papillitis is also a unilateral disease.
- If the disc has a blurred edge and the patient can see well, it may refer to **papilloedema**. It is usually bilateral, and frequently accompanied by retinal hemorrhage and dilated veins, as well as the disc, maybe indented. Papilloedema can indicate increased intracranial pressure.

Examination of the visual field

- The visual field is examined instrumentally in the ophthalmological practice. Not only the borders but also defects of the visual field (scotomas) can be examined with equipment.
- **Confrontal visual field testing**: comparing the boundaries of the patient's visual field with our own (hopefully normal) visual field. Only major visual field defects can be detected with a neurological bedside examination. The patient should be seated about 1 arm's length away, at the same height. Initially, both eyes are examined separately. Ask the patient to cover one eye and look at our forehead with the other eye. Close your eye opposite to the patient's covered eye. Place your hand outside the patient's visual field, and move it gradually forward. Ask the patient to indicate if he can see your finger. If you suspect that the patient is not cooperating well, you may ask him to touch your finger, when he can see it. Check the temporal, nasal, upper, and lower edge of the visual field. Repeat on the other eye. Using this technique, the examiner compares her/his visual field with that of the patient.
- After the separate examination of the two eyes, examine the visual field again, when both eyes are open.
- If the patient does not cooperate or he is comatose, use the oculopalpebral reflex for the examination of the visual field.

Interpretation of the results

- The visual field can be divided vertically into two parts: **nasal** and **temporal**. Defective vision or blindness in half of the visual field of one or both eyes is called **hemianopia**. If the visual field defect involves either the two right or the two left halves of the visual fields of both eyes, it is called

homonymous hemianopia. If the visual field defect affects different sides of the eyes (e.g., the right side is affected in one eye, and the left one is affected on the other), it is called **heteronymous hemianopia**.

- Easy role: Most chiasmal lesions produce heteronymous, while most postchiasmal lesions produce homonymous visual deficits.
- **Complete unilateral vision loss (amaurosis)** may refer to an ipsilateral pre-chiasmal lesion (Fig. 2. A.)
 - Damage of the eyes (e.g., vitreous hemorrhage)
 - Damage of the retina
 - Hemorrhage, retinopathy
 - Amaurosis fugax (microembolization, which usually quickly disappears)
 - Optic nerve damage
 - Papillary damage: chronic papilloedema, papillitis
 - Retrobulbar neuritis (demyelinating diseases, multiple sclerosis, Devic's disease)
 - Lesion of the anterior part of the optic nerve often may be a consequence of vasculitis (e.g., temporal arteritis)
 - Optic nerve atrophy: may be caused by chronic papillitis, papilloedema, Devic's disease in that phase which is accompanied by blindness, or tumor-induced compression
 - In the case of conversion unilateral functional vision loss may be mimicked (psychogenic or functional blindness).
- Lesion of the **optic chiasm** frequently results in **bitemporal (heteronymous) upper quadrantanopia** or **bitemporal (heteronymous) hemianopia** (Fig. 2. B.). It is usually caused by hypophyseal tumors, craniopharyngioma, or tuberculum sellae meningioma.
- Lesion of the **optic tract** results in contralateral **homonymous hemianopia** (Fig. 2. D.).
- Lesion of the **optic radiation** results in contralateral **homonymous hemianopia**. In the case of stroke, the area of the macula is usually intact, because the pole of the occipital lobe is supplied by the middle cerebral artery, while the other parts of the visual cortex are supplied by the posterior cerebral artery (Fig. 2. G.).
- **Homonymous quadrantanopia** may refer to a partial lesion of the optic radiation. The homonymous upper quadrantanopia develops in the case of a contralateral temporal lesion, while the homonymous lower quadrantanopia develops in the case of a contralateral parietal lesion (Fig. 2. E. and F.).
- The lesion of the upper part of the **calcarine fissure** leads to contralateral lower quadrantanopia, while the area of the macula remains intact. By contrast, the lesion of the lower part of the calcarine fissure leads to contralateral upper quadrantanopia (Fig. 2. E. and F.).
- In the case of lesion of the **occipital lobe**, the patient does not always realize the visual field loss, because the central vision may remain intact due to the bilateral representation (Fig. 2. G.).
- The lesion of the entire **occipital pole** results in cortical blindness.
- If you cannot observe visual field loss by examining both sides separately, but the patient fails to notice stimuli on one side (usually on the left) if examined simultaneously, this phenomenon is called **visual neglect** (visual inattention). It usually refers to subdominant (mostly right hemisphere) disturbance of parietal cortical functions.



Visual field examination: <https://www.youtube.com/watch?v=gWZ7Zf35r3s>

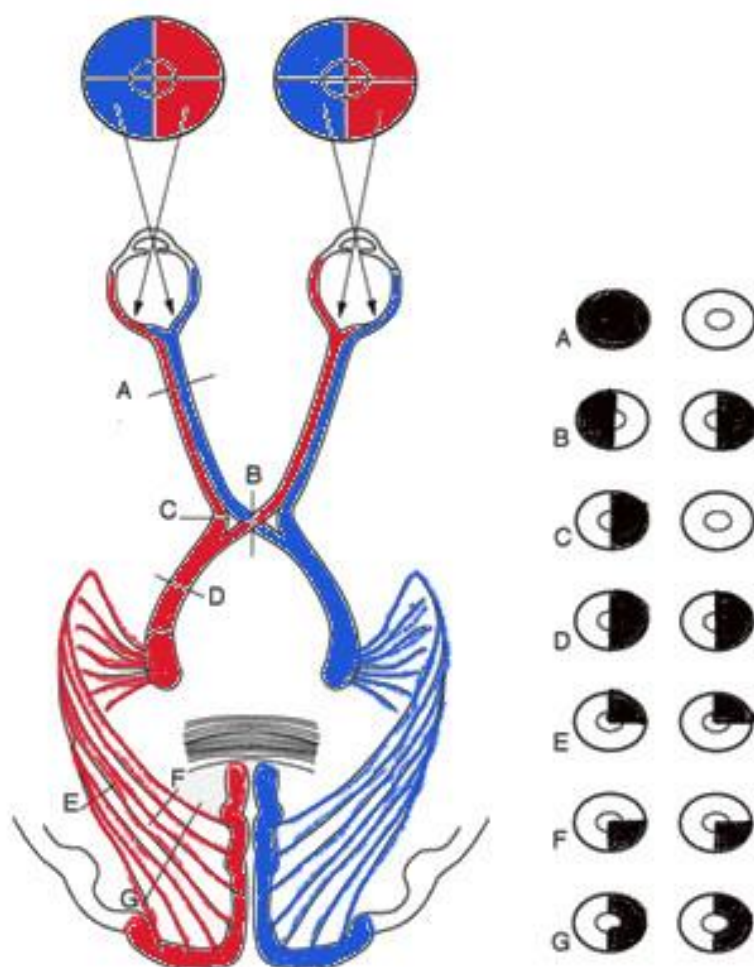


Figure 2. Types of visual field loss.

A. A pre-chiasmal lesion causes complete unilateral vision loss.

B. Lesion of structures that are central to the optic chiasm leads to bitemporal heteronymous upper quadrantanopia or bitemporal heteronymous hemianopia.

C. Lesion of the lateral aspect of the optic chiasm leads to ipsilateral nasal hemianopia.

D. Lesion of the optic tract leads to contralateral homonymous hemianopia.

E. Lesion of optic radiation or lower parts of fissura calcarina leads to contralateral homonymous upper quadrantanopia.

F. Lesion of optic radiation or upper parts of fissura calcarina leads to contralateral homonymous lower quadrantanopia.

G. Lesion of the occipital lobe can lead to contralateral homonymous hemianopia, but in most of the cases, the central vision remains intact.

Examination of reflexes

Pupillary reflex

The optic nerve is responsible for the afferent, whereas, the oculomotor nerve is responsible for the efferent limb of the pupillary reflex. Since the afferent part gives fibers for the vegetative nuclei of each oculomotor nerve (Edinger-Westphal nucleus bilaterally), the illumination of one eye produces myosis in both the ipsilateral (**direct pupillary reflex**) and the contralateral (**indirect pupillary reflex**) eyes.

Oculopalpebral reflex

The optic nerve is responsible for the afferent part, and the facial nerve is responsible for the efferent part of the oculopalpebral reflex. If a sudden object approaches the eyes, blinking (closing the eyes) is elicited to avoid injury of the eye. Oculopalpebral reflex examination is an important tool to evaluate the visual field in either comatose or non-cooperating patients.

Examination of the oculomotor nerve (III.)

The oculomotor nerve has both somatic motor fibers and vegetative motor (parasympathetic) fibers. The Edinger–Westphal nucleus innervates (parasympathetic function) the intraocular muscles (the iris sphincter and ciliary muscles). The somatic motor nuclei can be found at the level of the mesencephalon and innervate four oculomotor muscles (the medial, superior, and inferior rectus muscle, and the inferior oblique muscle), as well as the levator palpebrae superioris muscle.

- **External ophthalmoplegia:** All extraocular muscles are paralyzed.

- **Internal ophthalmoplegia:** The inner eye muscles are paralyzed.
- **Complete ophthalmoplegia:** Both inner and outer eye muscles are paralyzed.

Examination of the somatic motor functions

Ptosis

- Ptosis means drooping or falling of the eyelids. Because the oculomotor nerve plays an important role in eyelid opening, the impairment of the oculomotor nerve can cause ptosis. Of note, other causes (e.g. myasthenia gravis, myopathy, Horner's syndrome) can also cause ptosis.

Position of the eye

- In the case of unilateral lesion of the oculomotor nerve, the eye is in a characteristic down and lateral position, because the muscles innervated by the trochlear and abducens nerves are functioning. The patient usually reports diplopia, which worsens looking to the side contralateral to the lesion. If the ptosis is complete (and fully covers the pupil), the patient does not necessarily report diplopia and a compensatory head position cannot also be observed (Fig. 3.).

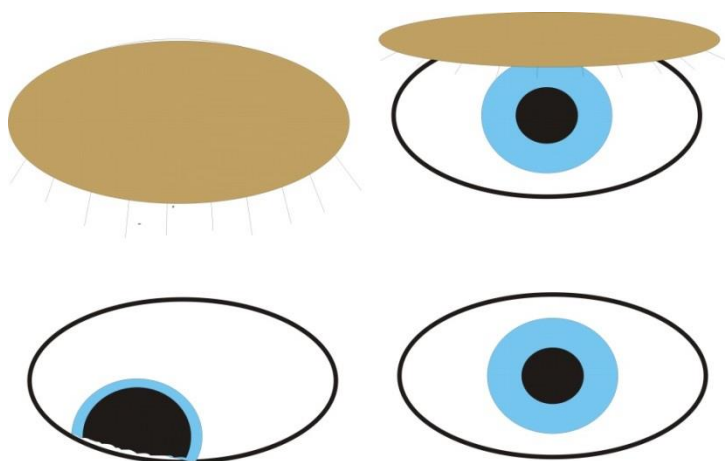


Figure 3. Position of the eye in the case of lesion of the right oculomotor nerve palsy. The patient does not report diplopia, because of the ptosis. When you lift the patient's eyelid, you can find a dilated pupil, which does not react to light, and the eye is in a characteristic downward and outward position.

Examination of the eye movements

- The examination of the eye movements is discussed in the chapter entitled "Examination of the eye movements".

Parasympathetic innervation

- **Internal ophthalmoplegia:** The inner eye muscles are paralyzed. The eye movements are intact, but the pupillary reflex cannot be elicited. Loss of accommodation results in blurred vision for near objects.
- Reflexes related to parasympathetic function are detailed in the chapter entitled "Examination of the eye".

Pupillary reflex

The optic nerve is responsible for the afferent part, and the oculomotor nerve is responsible for the efferent part of the pupillary reflex.

Accommodation reflex

The visual pathway running from the retina to the visual cortex is responsible for the afferent part, and the visual pathway running from the visual cortex via the Perlia nucleus to the oculomotor nerve is responsible for the efferent part of the accommodation reflex.

Convergence reflex

The visual pathway running from the retina to the visual cortex is responsible for the afferent part, and the visual pathway running from the visual cortex via the Perlia nucleus to the oculomotor nerve is responsible for the efferent part of the convergence reflex.

Causes of lesions of the oculomotor nerve

- Usually, only the innervation of the external muscles is injured, e.g., endocrine ophthalmoplegia due to diabetes or hypothyreosis.
- aneurysm (e.g., posterior common carotid artery)
- Tentorial herniation (In a comatose patient with unilateral complete oculomotor nerve lesion, wide and light-refractory pupil, one has to always consider increased intracranial pressure and tentorial herniation!)
- brainstem stroke (which impairs the motoric nuclei of the oculomotor nerve)
- inflammation or thrombosis in the cavernous sinus – pain, the involvement of cranial nerves III, IV, V/1, and VI
- Tolosa–Hunt syndrome – painful extraocular palsy, lesion of the cranial nerve V/1
- Fissura orbitalis superior syndrome – involvement of cranial nerves III, IV, V/1, and VI

Examination of the trochlear nerve (IV.)

The trochlear nerve is a pure motor nerve. Its nucleus can be found at the level of the mesencephalon, which innervates the superior oblique muscle. The fibers leave the nucleus, cross over, and emerge from the back of the brainstem.

Position of the eye

- In the case of paralysis, the impaired eye is in a slightly inward (medial) and upward position. To compensate for the vertical diplopia, the patient tilts his head towards the opposite side of the lesion. If you ask the patient to look down or you tilt the patient's head towards the affected side, the severity of diplopia will be increased (Fig. 4.).

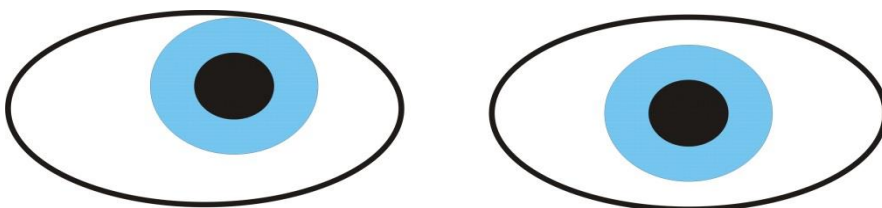


Figure 4. If the superior oblique muscle is damaged, the eye is in an upward and slightly medial position. In this case, the left trochlear nerve is affected because of the crossing over.

Examination of the eye movements

- The examination of the eye movements is detailed in the chapter entitled “Examination of the eye movements”.

Causes of lesions of the trochlear nerve

- The isolated trochlear nerve lesion is rare (mainly in pediatric problems).
- brainstem stroke
- trauma
- herpes
- inflammation or thrombosis in the cavernous sinus – pain, the involvement of cranial nerves III, IV, V/1, and VI
- Fissura orbitalis superior syndrome – involvement of cranial nerves III, IV, V/1, and VI

Examination of the trigeminal nerve (V.)

The trigeminal nerve is a mixed cranial nerve, i.e. it has sensory and motor functions as well. It has several nuclei and one ganglion:

- **Trigeminal ganglion (Gasser's ganglion):** pseudounipolar neurons. This sensory ganglion supplies the face anterior to the line of the ears. It has three major branches: the ophthalmic nerve (V_1), the maxillary nerve (V_2), and the mandibular nerve (V_3). It supplies the somatosensory sensation of the face in front of the ear (the area behind the ear is supplied by the C_2 and C_3 nerves). The trigeminal nerve supplies the nose, the oral cavity, and the maxillary sinus, as well as ensure the pain sensation of the anterior and medial part of the dura mater, and tactile and pain sensation of the tongue (Fig. 5.).
- **The principal (sensory) nucleus of the trigeminal nerve.** The main sensory nucleus of the palpation and two-point discrimination.
- **Spinal trigeminal nucleus.** This sensory nucleus receives information about temperature and pain from the ipsilateral face. It plays part in the process of migraine attacks.
- **The mesencephalic nucleus of the trigeminal nerve.** This nucleus processes the proprioceptive information from the masticatory muscles. The afferent fibers reach the nucleus via the mandibular nerve. It is responsible for the afferent part of the Masseter reflex.
- **Motor nucleus of the trigeminal nerve.** It is responsible for the innervation of the masticatory muscles and serves as the efferent part of the masseter reflex. It is analogous with the α -motor neuron of the spinal cord.

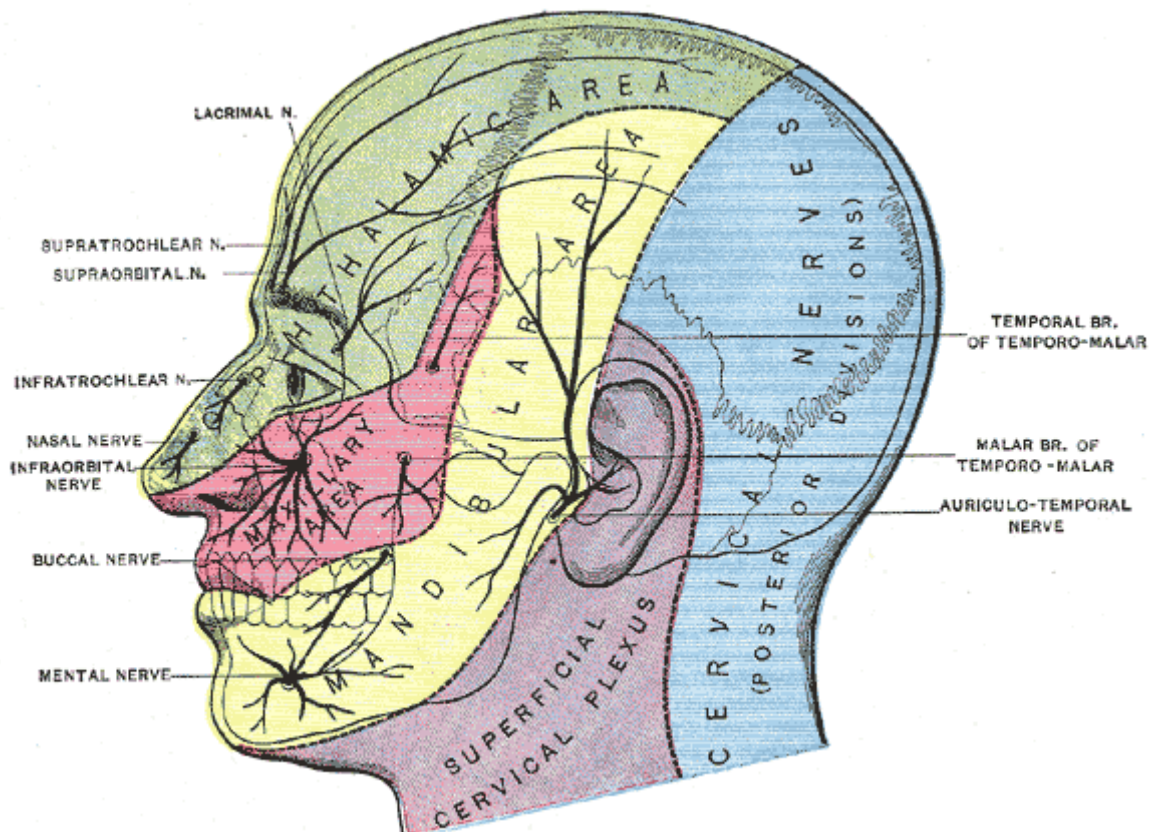


Figure 5. Sensory innervation of the face. (Source: Wikipedia.org)

Examination of the somatosensory function

- Pressure on the entry points of the trigeminal nerve branches (V_1 , V_2 , and V_3) may provoke pain in trigeminal neuralgia.
- The sensation of touch should be examined symmetrically at the area of the trigeminal nerve branches (V_1 , V_2 , and V_3) by smoothing with your finger.

- Examination of the pain sensation should be performed symmetrically with a toothpick.
- Examination with a heat stimulus should be used only if any abnormality was found during the examination of touch or pain sensation.
- Observe whether the sensory loss is unilateral (affects all areas of the V₁, V₂, and V₃ nerves), or is it localized to the supplying area of a single nerve.

Interpretation of the somatosensory function

- Unilateral V₁ lesion: herpes infection, cavernous sinus thrombosis
- Unilateral V₂ lesion: most commonly caused by trauma
- Unilateral V₃ lesion: most commonly due to basal tumor or meningitis
- Unilateral V₁, V₂, and V₃ lesions: brainstem lesion at the level of the pons, lesion of the geniculate ganglion, basilar meningitis

Examination of the motor function

- Ask about the muscle strength: Do you get tired of chewing?
- Examination of the muscle strength: Examine the muscle strength during the opening and closing the mouth.
- Examination of muscular trophy: Ask the patient to clench his jaw and palpate the temporal and masseter muscles.
- Ask the patient to open his mouth and try to move his jaw forward, the chin deviates towards the paretic pterygoid muscle.
- In the case of a peripheral lesion, the temporal and masseter muscles cannot be palpated at the side of the lesion.
- In the case of a central lesion, the masseter reflex becomes brisk.

Masseter reflex (jaw-jerk reflex)

Ask the patient to SLIGHTLY open his mouth. Check that he does not open his mouth COMPLETELY. Place your index finger over the patient's chin and tap your finger with a reflex hammer. In response, the masseter muscles will slightly jerk the mandible upwards in most of the patients. A brisk response may refer to upper motor neuron lesions.

Examination of superficial reflexes

Examination of the cornea reflex

- The presence of the cornea reflex is not tested routinely. However, it is necessary to be examined in the case of coma, Bell's palsy, or the suspicion of brainstem or cavernous sinus lesion.
- The trigeminal (ophthalmic, V/1) nerve is responsible for the afferent part, and the facial nerve is responsible for the efferent part of the cornea reflex.
- Examine the cornea reflex with a piece of cotton wool. If the patient is alert (non-comatose) explain to him what you are going to do. Ask the patient to look at the other direction, while you are touching the cornea with the piece of cotton wool. If it is possible, keep your hand and the piece of cotton wool out of the patient's visual field (in this case, you can avoid eliciting the oculopalpebral reflex instead of cornea reflex).
- Observe whether the touching of the cornea at one side produces blinking in both eyes or not.
- Ask the patient (if conscious), whether he could recognize the touching of the cornea equally on both sides.
- Causes for bilateral loss of corneal reflex can be due to a lesion at the level of the pons. However, in the cases of young comatose patients, be suspicious of the presence of contact lenses.

- Cause for unilateral loss of cornea reflex: unilateral loss of trigeminal (more precisely the ophthalmic nerve) and/or facial nerve response, unilateral space-occupying in the cerebellopontine angle. If the loss of cornea reflex is accompanied by loss of pain sensation, probably the trigeminal nerve is affected. If the pain sensation is intact, it is more probable that there is a facial nerve injury.



Cornea-reflex examination: <https://www.youtube.com/watch?v=1BPcpKfAJ60>



Trigeminal nerve examination: https://www.youtube.com/watch?v=HKlcjOCw3_8

Examination of the abducens nerve (VI.)

The abducens nerve is a pure motor cranial nerve. Its nucleus can be found at the level of the pons and innervates the lateral rectus muscle.

Position of the eye

- In the case of abducens nerve palsy, the affected eye is in a slightly inward position and is unable to abduct. To compensate for the horizontal diplopia, the patient tilts his head to the same side of the lesion (Fig. 6.).

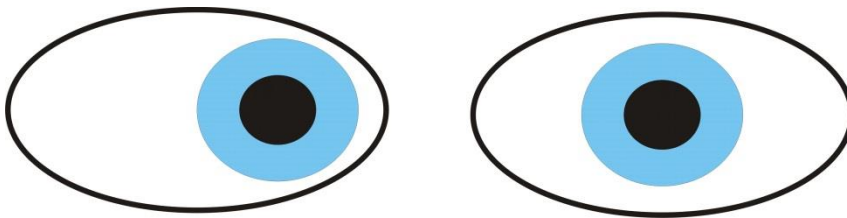


Figure 6. In the case of abducens nerve palsy, the pupil size is normal, but the eye is in a medial position.

Examination of the eye movements

- The examination of the eye movements is detailed in the chapter entitled “Examination of the eye movements”.

Causes of lesions of the abducens nerve

- increased intracranial pressure
- diabetes mellitus (ophthalmopathy)
- multiple sclerosis (nuclear impairment)
- brainstem stroke
- cranial fracture
- meningitis (mainly basilar meningitis)
- inflammation or thrombosis – pain in the area of the cavernous sinus, the involvement of cranial nerves III, IV, V/1, and VI
- Fissura orbitalis superior syndrome – involvement of cranial nerves III, IV, V/1, and VI

Examination of the facial nerve (VII.)

The facial nerve is a mixed cranial nerve, i.e. it has somatomotor, somatosensory, taste sensory, and vegetative functions:

- Somatic motor innervation of the facial mimic muscles (as well as the stylohyoid muscle, digastric muscle, and a certain part of the platysma muscle). The facial nerve is responsible for eyelid closure, as well.
- Innervation of the stapedius muscle (stapedius reflex)
- Somatosensory innervation of certain parts of the outer ear, the outer part of the tympanic membrane and certain parts of the ear canal

- Parasympathetic innervation of the nasal mucous membrane, lacrimal gland and the sublingual and the submandibular salivary glands (nasal mucus production, lacrimation, salivation)
- Taste sensation from the anterior two-thirds of the tongue (chorda tympani)

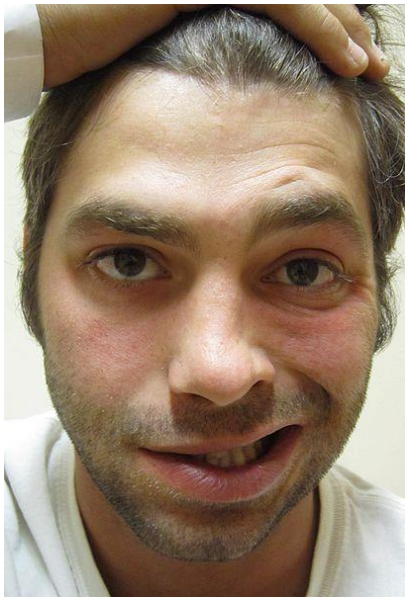

Figure 7. Right-sided peripheral facial palsy. The patient is trying to wrinkle his forehead and smile broadly at the same time. Source: Wikipedia.org

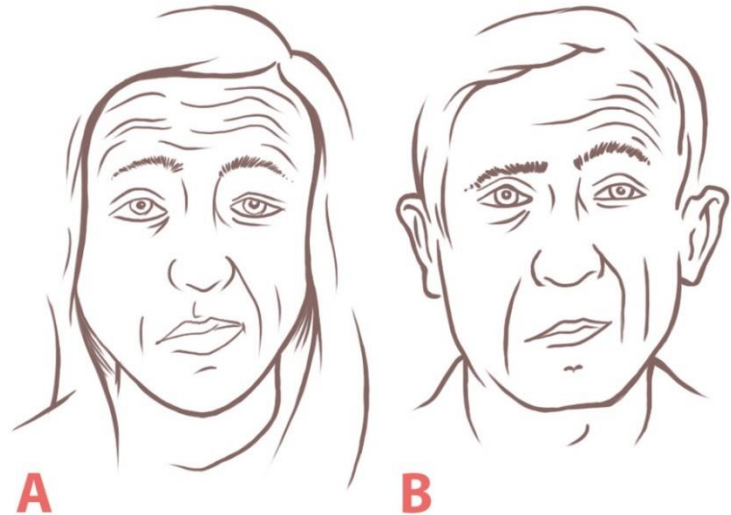


Figure 8. Comparison of central (A) and peripheral facial nerve palsy. In the case of central facial palsy, the patient can raise her eyebrows, wrinkle her forehead, and close her eyes. In the case of peripheral facial palsy, the patient is unable to wrinkle his forehead, raise his eyebrow, and close his eyes completely.

Figure 9. Examination of peripheral facial palsy. Examination of the spontaneous facial expression, mouth movements (laughing), and closing of the eye. The upward movement of the eye is visible (Bell's phenomenon). Source: A Text-book of the practice of medicine. Hermann Eichhorst, W.B. Saunders, 1901




FIG. 60.—Facial expression of a man, 55 years old, presenting severe left-sided traumatic peripheral paralysis of the facial nerve; from a photograph (personal observation, Zurich clinic).





FIG. 61.—The same patient shown in Fig. 60, on laughing.



The same patient shown in Figs. 60 and 61, when an attempt is made to close the eyes.

Examination of the somatic motor function of the facial nerve

- Check the patient's face. Is there any facial asymmetry, differences in the forehead wrinkles, angles of the mouth, or blinking.
- Ask the patient to show his teeth, whistle, and frown. Search for asymmetry.
- Ask the patient to close his eyes. Try to open them gently. Note whether it is equally strong on both sides.
- Ask the patient to blink frequently. Notice any slowness of the closing phase compared to the contralateral side because this can indicate incipient peripheral facial palsy.
- Examination of **Bell's phenomenon**: While the patient's eyes are open, hold the upper eyelids, and ask the patient to close his eyes. If the peripheral innervation is intact, an upward movement of the eyes can be noticed. This physiological phenomenon is preserved in peripheral facial palsy. However, Bell's phenomenon cannot be revoked in the case of lesion of the superior rectus muscle (or oculomotor nerve impairment).

Interpretation of the motor function of the facial nerve:

- The muscles responsible for the frowning and the orbicular muscles have bilateral supranuclear innervation (corticobulbar pathways). Therefore in the case of unilateral central facial palsy, the frowning, eye-closing, and blinking remain normal on both sides. Consequently, disturbances of the frowning and closing of the eye develop only in the case of ipsilateral peripheral facial palsy.
- The perioral muscles and the platysma muscle have only unilateral innervation, therefore they are affected both in central and peripheral facial palsy.
- In the case of central facial palsy, the contralateral supranuclear lesion can be assumed, while in the case of a peripheral paresis, an ipsilateral lesion can be supposed.
- The unilateral peripheral facial palsy is called **Bell's palsy**. In the initial stage of peripheral facial palsy, the patient may be still able to close his eyes normally, but the speed of blinking is slower than that of the contralateral eye. If the patient is unable to close his eyes completely, it is called **lagophthalmos**.
- The facial nerve is responsible for closing the eyes, therefore its lesion does NOT result in ptosis. Ptosis can be caused by oculomotor nerve palsy, Horner's syndrome, lesion of the neuromuscular junction, or myopathy.
- Bilateral peripheral facial palsy can be caused by neuroborreliosis, Miller Fisher syndrome, carcinomatous meningitis, or neuromuscular junction disorders.
- Unilateral central facial palsy and weakness of limbs: contralateral supranuclear lesion (stroke, tumor).

- Unilateral peripheral facial palsy and contralateral weakness of limbs: brainstem lesion (alternating syndrome – Millard–Gubler syndrome).
- Bilateral central facial palsy with dysarthria, dysphagia, and compulsive weeping: pseudobulbar paresis (severe bilateral supranuclear vascular lesion, which is commonly accompanied by vascular dementia and symptoms of lower nerve injury).
- The presence of mild facial asymmetry refers not necessarily imply facial nerve lesion. Especially not, if symmetric movements can be observed in the case of voluntary innervation. It is called **facial asymmetry**. In this case, ask for one of the patient's photo identification cards to evaluate whether the facial asymmetry is normal or a new phenomenon. If the asymmetry is observable in the photo, it can be considered as either remnant of an earlier lesion or normal variation.
- In Parkinson's disease, a reduced degree of facial expressions can be observed. It cannot be considered as paresis, it is called **hypomimia**.
- Spontaneous **orofacial dyskinesia** or **blepharospasm** may appear in certain types of dystonia and dyskinesia.
- Facial spasms (**clonisation**) can appear during epileptic seizures.
- **Tics** can be observed in Tourette's syndrome.
- **Synkinesis**: If the reinnervation not properly develops after a peripheral facial palsy, synkinesis can be observed. E.g., the eyes become closed, when the patient smiles, or eating provokes excessive lacrimation (the so-called "crocodile tears"). The explanation of the latter can be the fact that the lacrimal glands are reinnervated by the newly developed fibers.

Examination of the sensory function of the facial nerve

- Impairment of somatosensory perception: the touch of the external auricular canal and the outer part of the tympanic membrane (e.g., with a piece of cotton wool). In the case of Bell's palsy, examine the tympanic membrane (whether there are any herpes blisters).
- The taste sensation is not examined routinely. You can ask the patient, whether he can recognize salty and sweet tastes. If you examine the patient's taste sensation, use ear picks dipped into salty and sweet liquids. The patient's eyes should be closed (not to be able to know, whether you use flavored or unflavored ear-picks). Ask the patient, whether he can recognize any taste (sensation), and the type of taste (cognitive process). The two sides should be examined separately. Ask the patient to rinse out his mouth after each taste to neutralize the previous one.

Facial nerve reflexes

Corneal reflex

- In the case of unilateral peripheral facial palsy, the patient can recognize touching of the cornea at the same level (it results in pain), but there is no blinking at the side of the injured facial nerve.

Oculopalpebral reflex, blink reflex

- An object appearing suddenly on the visual field results in blinking. The reflex aims to protect the eye from foreign bodies. The optic nerve (superior colliculus) is responsible for the afferent part, and the facial nerve is responsible for the efferent part of the oculopalpebral or blink-reflex. It can also be used to evaluate severe visual field problems in non-cooperative patients.

Stapedius reflex (or acoustic reflex)

- The vestibulocochlear nerve (dorsal trapezius nucleus) controls the contraction of the stapedius muscle via the facial nerve in response to high-intensity sound stimuli. This reflex plays part in the reduction of the noise nuisance caused by high-intensity sound stimuli. At the ENT, it can be examined instrumentally. Loss of the reflex may result in hyperacusis or tinnitus.


Localization of the level of the lesion in the case of peripheral facial palsy

- After the stylomastoid foramen: only motor symptoms
- At the level of chorda tympani: dysgeusia and motor symptoms
- At the level of stapedius muscle: hyperacusis, dysgeusia and motor symptoms
- At the level of greater petrosal nerve: disturbance of the production of saliva and tears, hyperacusis, dysgeusia, and motor symptoms
- The inner part of the internal auditory canal: lesion of the vestibulocochlear nerve (vertigo), hearing loss, disturbance of the saliva and tear production, hearing disorders, dysgeusia, and motor symptoms

 **Facial nerve examination:** <https://www.youtube.com/watch?v=syXSUYfo94>

 **Bell's palsy with lagophthalmos:** <https://www.youtube.com/watch?v=GKOLVKuw6Ew>

 **Incomplete (recovering) Bell's palsy:** <https://www.youtube.com/watch?v=Lq5dhvldTgQ>

 **Central facial palsy:**

Examination of the vestibulocochlear nerve (VIII.)

The vestibulocochlear nerve is a pure sensory nerve emerging from the basis of the pons.

Examination of hearing

- The external auditory canal can be examined with an otoscope (e.g., in the case of Bell's palsy).
- During the conversation with the patient, it usually becomes apparent quickly, if the patient has hearing disturbances.
- The simplest hearing test: Ask the patient to cover one of his ears. Rub your fingers together in front of the other ear. Normally the patient should hear this noise. Examine the other ear in the same manner.
- Precise, objective hearing tests are the audiometry and the BERA.

Rinne test

- This test compares the perception of sounds transmitted by air conduction to those transmitted by bone conduction. Place a vibrating calibrated tuning fork against the patient's mastoid bone and once he cannot hear the signal, quickly place the still vibrating tuning fork in front of the auditory canal. Normally the patient is still able to hear the sounds transmitted by air conduction.

Weber's test

- Place a vibrating calibrated tuning fork against the top of the patient's head. Normally the patient hears the sound equally on both sides. In the case of conductive hearing loss, the patient hears the tuning fork louder in the defective ear (lateralization in Weber's test).

Interpretation of the results

- **Conductive hearing loss.** Lateralization of the defective ear in Weber's test. In the Rinne test, the bone conduction is better than the air conduction, because the earwax and the internal otitis do not affect the bone conduction, but decrease the air conduction.
- **Sensorineural hearing loss.** Lateralization of the healthy ear in Weber's test. Rinne test is positive at the affected side (the high-pitched sounds are more affected).

Examination of the vestibular system

It is detailed in the chapter entitled "*Vertigo and examination of the vestibular symptoms*".

Examination of the glossopharyngeal nerve (IX.)

The glossopharyngeal nerve is a mixed sensory and motor cranial nerve emerging from the medulla oblongata.

- It is responsible for the taste sensation of the posterior one-third of the tongue.
- Somatosensory: the general sensation of the tympanic cavity, the walls of the upper pharynx, the tonsils, and the soft palate.
- Somatomotor: stylohyoid muscle, innervation of the pharyngeal and laryngeal muscles together with the vagus nerve.
- Vegetative and sensory innervation of the carotid branch
- Saliva secretion of the parotid gland.

From neurological aspects, its somatosensory and somatic motor functions can be examined.

- Pharyngeal reflex.
- Soft palate reflex.

Examination of the vagus nerve (X.)

The vagus nerve is a mixed sensory and motor cranial nerve emerging from the medulla oblongata.

- Sensations of the posterior fossa dura
- Sensations of the posterior wall of the external auditory canal
- Innervation of the pharyngeal and laryngeal muscles
- Parasympathetic innervation of the heart, lung, stomach, liver, kidney, small intestine, and a certain part of the large intestine

In clinical practice, the motor function can be examined physically:

Examination of the uvula

- Ask the patient to open his mouth and examine the position of the uvula. Ask the patient to say “ahh” and observe, whether the uvula deviates.
- Deviation of the uvula during innervation refers to vagus nerve injury (the uvula deviates towards the unaffected side).

Cough

- Ask the patient to cough. In the case of any disturbance of the vocal cord innervation, a “weak” cough can be heard.

Speech

- The patient’s voice is stronger and louder in unilateral vocal cord palsy. In the case of bilateral vocal cord palsy, the patient may only be able to whisper.

Swallowing

- Ask the patient, whether he has difficulties with swallowing, if he has to cough during eating or drinking, or he experiences some liquids come back up through his nose during drinking.
- Ask the patient to drink a glass of water. Observe, whether he can swallow it without coughing.

Vocal cords

- They can be examined with direct or indirect laryngoscopy at the otology.

Pharyngeal reflex and soft palate reflex

- Ask the patient to open his mouth. Press down the patient's tongue by a tongue depressor. Touch both sides of the pharyngeal wall and soft palate by another tongue depressor or a cotton-tipped swab.
- Depending on the place of touching, the trigeminal nerve (mandibular nerve) or the glossopharyngeal nerve is responsible for the afferent part, and the glossopharyngeal or vagus nerve is responsible for the efferent part of these reflexes.
- Can the patient feel it equally? Is the pharyngeal reflex the same on both sides?
 - Absent pharyngeal reflex may refer to a peripheral lesion (the glossopharyngeal nerve is the afferent and the vagus nerve is the efferent limb).
 - Increased pharyngeal reflex. Upper motor neuron lesion, pseudobulbar symptoms (pseudobulbar paresis).
 - However, the presence of a normal pharyngeal reflex does not exclude difficulty in swallowing.

 Examination of the CN 9 & 10: https://www.youtube.com/watch?v=8VDA5n0d_IM

Examination of the accessory nerve (XI.)

The accessory nerve is a pure motor cranial nerve. The fibers emerge from two different regions: the medulla oblongata (intracranial) and the myelon (C₂₋₅, spinal). A portion of the intracranial nerves joins the vagus nerve and takes part in the innervation of the laryngeal muscles.

- The trapezius muscle has mainly contralateral innervation.
- The sternocleidomastoid muscle has mainly ipsilateral innervation.

Examination of the trapezius muscle

- Palpate the trapezius muscle. Observe, whether hanging shoulder is present. Ask the patient to lift his shoulder, while you are pressing down it. Compare the muscle strength of both sides.

Examination of the sternocleidomastoid muscle

- Check and palpate the sternocleidomastoid muscle. Ask the patient to turn his head in such a position that the temporomandibular corner reaches the shoulder, and then try to push it back into the central position with your hands. Observe the extent of the resistance, and asymmetry.

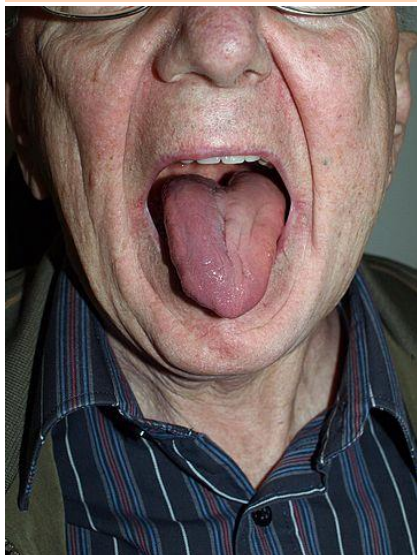
Evaluation of the results

- Unilateral sternocleidomastoid and trapezius muscle impairment usually refer to the peripheral lesion. Common causes include trauma, previous operation, or irradiation.
- Unilateral sternocleidomastoid and trapezius muscle impairment accompanied by signs of the vagus and glossopharyngeal nerve impairment: jugular foramen lesion.
- Unilateral sternocleidomastoid muscle and contralateral trapezius muscle impairment refer to central lesion ipsilateral to the sternocleidomastoid lesion.
- Bilateral sternocleidomastoid muscle atrophy and weakness: myotonic dystrophy, facioscapulohumeral muscular dystrophy, motor neuron disease.
- Unilateral isolated trapezius muscle weakness is usually of peripheral origin, but it may be rarely central as well.
- If the peripheral accessory nerve impairment is responsible for the trapezius muscle weakness, usually only the upper part of the muscle is atrophied, because the lower part is innervated by the cervical plexus as well.
- Unilateral isolated sternocleidomastoid muscle impairment: most commonly traumatic.

- Unilateral increased trophic and hyperactivity of sternocleidomastoid muscle: dystonia.

Examination of the hypoglossal nerve (XII.)

The hypoglossal nerve is a pure motor nerve; it emerges from the medulla oblongata. The motor nucleus receives the supranuclear innervation mostly from the contralateral, slightly from the ipsilateral hemisphere, except for that branch of the hypoglossal nerve which innervates the genioglossus muscle. Because this receives only contralateral supranuclear innervation, in the case of supranuclear impairment the tongue deviates towards the contralateral side (central hypoglossal nerve palsy).



Examination of the tongue

- Ask the patient to open his mouth, but initially, the tongue should be at rest, thus the fasciculation and atrophy can be observed.
- In the case of tongue atrophy, the central fossa widens. It is the edge of the tongue that starts to become atrophied at first, and some retractions can be seen at the outline of the tongue.
- Ask the patient to stick out his tongue, and observe whether it deviates or not.
- Ask the patient to move his tongue from side to side then up and down. Observe, whether there is an asymmetry between the movements.

Figure 10. Peripheral paresis of the hypoglossal nerve.

Interpretation of the results

- A tongue tremor is common during sticking out the tongue, which is usually confused with fasciculation. For this reason, the presence of fasciculation is examined only in the rest position of the tongue.
- Unilateral lower motor neuron lesion: the tongue deviates towards the side of the lesion.
- Unilateral upper motor neuron lesion: the tongue deviates towards the opposite side of the lesion; it is usually accompanied by hemiparesis.
- Bilateral lower motor neuron lesion: Atrophy, fasciculation, and tongue weakness.
- Bilateral upper motor neuron lesion: Tongue weakness, difficulty swallowing, and speech disorder. There is no atrophy or fasciculation. It is usually accompanied by increased masseter and pharyngeal reflexes and crying attacks (pseudobulbar paresis).

Examination of the eye

During the examination of the eye, several cranial nerve functions are examined simultaneously.

Examination of the eyelid

Observe the eye, and ask the patient to blink several times subsequently. Ptosis can be provoked by looking up for a longer period (eye fatigue test, maybe positive e.g. in myasthenia gravis).

- **Lagophthalmos.** It is the inability to close the eyelids completely; it is characteristic of peripheral facial nerve palsy. In the cases of incomplete lagophthalmos, it is usually accompanied by decreased or slow blinking compared to the other side.
- **Ptosis.** Drooping of the eyelid due to muscle weakness. Ptosis can be provoked by a sustained upward gaze (eye fatigue test).

- **Eyelid-opening apraxia.** The eye is closed unintentionally, and the patient is unable to open it intentionally. After manual opening, he can normally blink for a while. It is a cortical dysfunction (apraxia), not a peripheral muscle weakness, or disturbance of innervation.
- **Blepharospasm.** It is an involuntary closure of the eyelids (it affects especially the orbicularis oculi muscle), a special type of dystonia.

Interpretation of the results

- Ptosis may be caused by oculomotor nerve injuries, or disturbance of the sympathetic innervation or impairment of the neuromuscular junction, or myopathy.
- The most common cause of an isolated, unilateral, long-standing ptosis is a previous trauma or congenital origin if it is not accompanied by eye movement disorder.
- Unilateral ptosis accompanied by an abnormal pupil refers to the lesion of the oculomotor nerve or the sympathetic fibers. If the oculomotor nerve is affected, the pupil is dilated (**mydriasis**), while in Horner's syndrome it is narrow (**myosis**).
- In the case of bilateral ptosis, myopathy or impairment of the neuromuscular junction has to be suspected.
- In older people, the bilateral, slightly drooping eyelids may be normal. However, in this case, neither the clinical picture nor the fatigue test reveals any impairment.
- Unilateral or bilateral, fluctuating ptosis may refer to damage to the neuromuscular junction.
- Ptosis can be increased by looking up (fatigue test) in myasthenia gravis. It improves or stops after giving intravenous edrophonium (Tensilon).

Examination of the pupil

Examine the shape, size, and asymmetry of the pupils in a moderately lit room.

Size of the pupil

- **Isocoria:** Equality in the size of the two pupils. **Anisocoria:** Inequality in the size of the two pupils (Figure 11).
- In conscious patients, the anisocoria may be normal if the size-difference is smaller than 2 mm. In a comatose patient, the anisocoria smaller than 2 mm has to be considered as pathologic, as long as the opposite is not proven.
- Unilateral, maximally dilated pupils, which do not react to light: tentorial herniation (oculomotor nerve damage)
- In the case of a comatose patient with unilateral light-refractory and maximally dilated pupil, one should always consider the possibility of tentorial herniation and increased intracranial pressure.
- Bilateral, maximally dilated pupils, which do not react to light: brainstem lesion, or atropine-like substances in both eyes (e.g., after ophthalmological examination)
- Mild dilated fixed pupil: lesion of the mesencephalon
- Tiny, pinpoint pupil: pons lesion, opioids
- Small, but reactive pupil: thalamus lesion

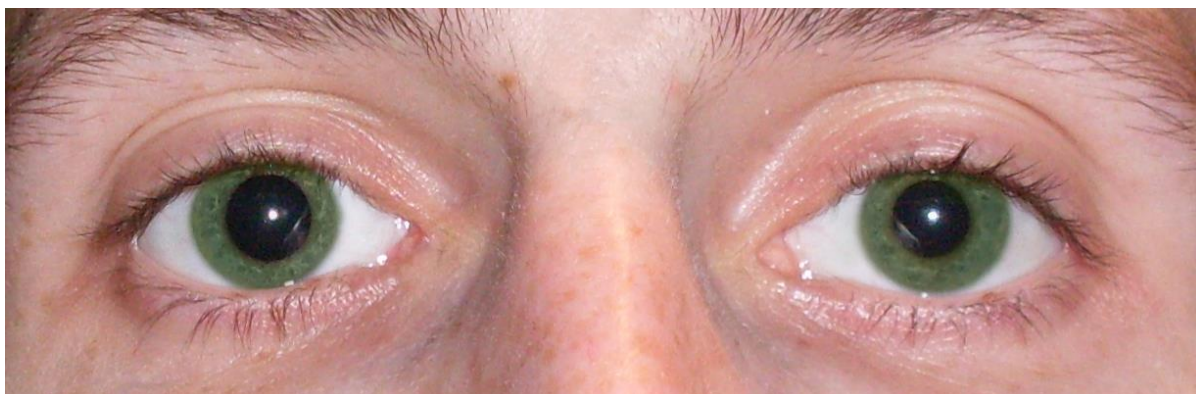

Figure 11. Anisocoria.

Examination of the pupillary reflex

Examine the pupillary reflex in a dark or dimmed room. Place your hand between the patient's eyes.

- Observe the shape and size of the pupils, and the presence of anisocoria.
- Observe the direct and consensual pupillary reflex in both eyes. Lighting into one of the eyes constricts not only the affected pupil (direct pupillary reflex) but also the contralateral one (indirect or consensual pupillary reflex).
- Swing continuously a bright light quickly from one of the eyes to the other. If one of the patient's pupil constricts less than the other (Marcus Gunn pupil), it may refer to a lesion before the chiasma of the optic nerve.

Interpretation of the results

- Normally both direct and indirect (consensual) pupillary reflex leads to myosis.
- **Optic nerve injury:** Neither the direct nor the indirect pupillary reflex can be elicited by light on the affected side. However, both the direct and indirect pupillary reflex can be elicited at the unaffected side. It refers to the preserved function of the oculomotor nerve at the affected side.
- **Marcus-Gunn pupil.** It is caused by afferent (prechiasmatic optic nerve) lesion. The pupil of the affected side does not constrict in the same way, as the contralateral one, if you swing the light from one of the eyes to the other one.
- **Absolute pupillary defect.** The patient perceives the light, but neither the pupillary reflex nor the accommodation can be elicited. It can result from botulism, cocaine intoxication, or complete damage of parasympathetic fibers of the oculomotor nerve.
- **Oculomotor nerve damage:** Maximally dilated pupil, which does not react to light. If the outer eye muscles are also affected, it is accompanied by ptosis, and downward-outward deviating bulbus. Unilateral, dilated pupil, which does not respond to light, may refer to tentorial herniation.
- **Horner's syndrome:** Constricted pupils (myosis), exophthalmos, ptosis, anhidrosis. Always consider sympathetic innervation problems which can be caused by dissection of the carotid artery, superior cervical ganglia, hypothalamus, cervical space-occupying, or a Pancoast tumor.
- **Hippus.** It is a rhythmic, but irregular dilating and contracting pupillary movements, which are independent of light. It may be normal but may appear in uremia and hepatic cirrhosis as well.

Examination of the convergence

Place your finger about 1 meter in front of the patient's eye. Ask the patient to look at your finger. Move your finger slowly towards the patient's face. The accommodation and the pupil constriction develop simultaneously.

Examination of the accommodation

Ask the patient to look into the distance. Place your finger in front of the patient's eye in the midline, and ask him to look at your finger. Hereby, the eyes converge and the pupils constrict.

Examination of the eye movements

It is worth differentiating several types of eye movements:

- **Spontaneous, searching eye movements.** They are the patient's spontaneous eye movements, e.g., he looks around in the consulting room. The searching eye movements can be observed during the obtainment of the anamnesis as well.
- **Eye movements following verbal orders.** Ask the patient to look in all four directions (up, down, left, and right).
- **Tracking eye movements, smooth pursuit.**
- **Reflex eye movements.** In the case of unconscious patients, the oculocephalic reflex (doll's eyes reflex) can provide important information regarding the function of the brainstem. If the consciousness is maintained, and we find gaze disturbance (e.g., vertical gaze palsy), the examination of reflex eye movements may also help to identify the location of the lesion.

Neural centers responsible for eye movements, gaze centers

- Voluntary eye movements: frontal lobe (Brodmann's area 8).
- Occipital lobe: visual reflexive eye movements (foveal fixation of the image of the object).
- Horizontal reflex eye movements: pontine gaze center.
- Vertical reflex eye movements: mesencephalic gaze center (the interstitial nucleus of Cajal).
- Medial longitudinal fasciculus: It is the neural pathway between the eye movement nuclei responsible for the coordinated eye movements.

Examination of the eye movements

The convergence of the eyes

- Observe the convergence. of the eyes at rest and marginal positions (conjugate eye movement vs. dysconjugate eye movement).
- Dysconjugate eye position: strabismus (in this case usually there is no diplopia), or symptoms of peripheral cranial nerve palsy (accompanied by diplopia).
- Skew deviation: a vertical misalignment of the eyes, it may refer to brainstem lesion.

Fixation

- During fixation, ask the patient to focus to a point for 15-30 seconds. The appearance of horizontal jerks (square wave jerks) may refer to cerebellar disorders, MSA (multiple system atrophy), or PSP (progressive supranuclear palsy).

Directed eye movements

- Ask the patient to look up and down, then left and right.

Tracking eye movements, smooth pursuit

- Stand about 1 meter away from the patient. Hold gently the patient's chin with one of your hands to prevent movement of his head. Ask the patient to follow your finger (or an object) with his eyes. Move your hand slowly upward, downward, right, and left. Examine smooth pursuit both together and separately on both eyes.
- The eye movements are normally continuous and conjugate.
- Is the movement of the eye continuous? Are there any pauses, which may refer to cerebellar lesions or side effects of drugs (e.g. antiepileptics).
- Whether **nystagmus** is present or not?
- Can any signs of **cranial nerve palsy** be seen?

- Does the patient complain of **diplopia**?
- Whether a **gaze palsy** is present or not?

Saccade

- **Saccade**: rapid conjugate eye movements.
- Place your right and left index finger to the two sides of the patient's visual field. Ask the patient to look ahead and not to move his head during the examination. Subsequently, ask the patient to look at your moving finger. At first, move your right finger then the left one. It is usually necessary to repeat the test several times. Observe the followings:
 - **Latency**. How fast is the initiation of eye movements?
 - **Speed**. Are the eye movements slow or fast?
 - **Precision**.
 - **Normally** the gaze gets exactly to the target.
 - **Undershoot saccade**. The gaze stops before the target, then corrects. Possible causes: Parkinson's disease, Huntington's disease, or other neurodegenerative disorders.
 - **Overshoot saccade**. The gaze stops beyond the target, then corrects. Cause: cerebellar lesion.

Diplopia

- In the case of double vision (diplopia), always examine the eye movements separately on both eyes. If the patient has double vision even when he is seeing with only one eye, it usually refers to ophthalmological causes (lens, vitreous body, or macula), or rarely bilateral occipital lobe lesion, but psychogenic causes also should be taken into consideration.
- Peripheral (nucleus of the motor nerve, cranial nerve, neuromuscular junction, or eye muscle) lesions may lead to diplopia. On the other hand, supranuclear or internuclear lesions of gaze centers usually do not cause diplopia.
- The diplopia is the greatest towards the direction of the paretic muscle. The cause of horizontal double vision is usually lesion of the oculomotor or abducens nerves, while the cause of the vertical double vision is usually the lesion of the oculomotor or trochlear nerves.
- Diabetes, vasculitis, migrainous attack, neuritis, aneurism, or intracranial pressure increase may be in the background of cranial nerve paralysis.

Gaze palsy

- Paralysis of the **frontal gaze center**. The patient is looking at his own "focus", he is unable to look voluntarily into the opposite direction. However, the reflex eye movements (oculocephalic reflex, caloric testing) can be elicited in all directions.
- **Supranuclear vertical gaze palsy**. The patient is unable to look vertically; the downward gaze is usually more frequently affected. However, the reflex eye movements (oculocephalic reflex) can be elicited in all directions.
- Impairment of the **mesencephalic gaze center**. Vertical gaze palsy, which cannot be overcome by either voluntarily or reflexively.
- Impairment of the **pontine gaze center**. Horizontal gaze palsy, which cannot be overcome by either voluntarily or reflexively.

Nystagmus

- It is an involuntary oscillation of the eyes, which is induced by the slow movement of the eye (slow component) and followed by a rapid correction in the opposite direction (fast component).
- It is detailed in the chapter entitled "Vertigo and examination of the vestibular symptoms".

Reflex eye movements

Oculocephalic reflex (doll's eyes phenomenon)

- The oculocephalic reflex aims to fixate an object on the fovea. To be able to elicit this reflex, the brainstem reflex centers should be intact.
- Before the examination of this reflex, make sure that there are no injuries, fractures, or joint instabilities of the cervical spine. In other cases, you may cause severe lesions of the cervical spine.
- If the patient does not cooperate (e.g., he is comatose), first of all gently lift the eyelids. While the patient is lying on his back, turn his head quickly to the right. If the brainstem is intact, the eye keeps fixing on the target area, if it is damaged, the eye moves passively together with the head. Repeat the maneuver in the opposite direction (left).
- The oculocephalic reflex is suitable for diagnosing supranuclear gaze palsies as well. E.g., in PSP (Progressive Supranuclear Palsy), where vertical supranuclear gaze palsy may develop, the patient is unable to look downwards intentionally. In this case, ask the patient to look at the center of your forehead. If you raise the head upwards and the reflexive brainstem eye movements are intact, the patient will be able to look at your forehead, i.e. looking downward as a result of a reflex.

Vestibuloocular reflex








- Can be examined by both Halmágyi test and caloric testing
- First of all, make sure that the patient's eardrums are intact.
- Pour 20-50 ml cold water into the outer ear canal.
- Normally the eyes deviate towards the stimulus and then turn to the other direction with a quick nystagmic jerk (i.e. the nystagmus as opposed to the direction of the stimulus).
- Pathological: if it cannot be elicited or dysconjugate gaze develops.

Internuclear ophthalmoplegia (INO)

- Internuclear ophthalmoplegia is caused by the lesion of medial longitudinal fasciculus (MLF). Because the two MLF are close to each other, usually both of them are damaged at the same time (bilateral INO).
- The eye at the side of the affected MLF is unable to adduct, while nystagmus can be seen on the other side.
- It can be considered as one type of supranuclear gaze palsy, therefore usually it is not accompanied by diplopia.
- The most common causes include MS or brainstem glioma in young patients and brainstem stroke in older patients.
- If one of the abducens nuclei is also damaged beside the bilateral MLF, the horizontal eye movement of one eye is completely lost, and it is limited on the other one, while the latter is accompanied by monocular gaze-evoked nystagmus. It is also called as „One and a half” syndrome, and it can be elicited by MS.

Useful videos related to the neurological examination of the eye and eye movements

- ▶ A complete examination of the eyes: <https://www.youtube.com/watch?v=enCHKVi72Uk>
- ▶ Oculomotor nerve palsy (peripheral): https://www.youtube.com/watch?v=AEL0xeJ_NSw
- ▶ Trochlear nerve palsy: <https://www.youtube.com/watch?v=6K1733HbaTw>
- ▶ Abducens nerve palsy: <https://www.youtube.com/watch?v=PI2ozPSWfHs>
- ▶ Ocular symptoms in myasthenia gravis: <https://www.youtube.com/watch?v=5UN-EHVXvBc>
- ▶ Normal and abnormal eye movements: <https://www.youtube.com/watch?v=rRDDKKqkdTg>

-  Pupillary reflex examination: <https://www.youtube.com/watch?v= 0oC1P4sqBQ>
-  Abnormal pupillary reactions: <https://www.youtube.com/watch?v=sINxEAGpvRQ>
-  Blepharospasm: <https://www.youtube.com/watch?v=hGesxOGNdfY>
-  Supranuclear (vertical) gaze palsy: <https://www.youtube.com/watch?v=JIWSilgPvc>
-  Preserved oculocephalic reflex: https://www.youtube.com/watch?v=L_Sc_MOZVoU
-  abnormal oculocephalic reflex: <https://www.youtube.com/watch?v=KslG5z-xIR8>
-  Internuclear ophthalmoplegia: <https://www.youtube.com/watch?v=tIOyFsBwUuY>

Vertigo and examination of the vestibular symptoms

- **Nystagmus.** Involuntary, rhythmic oscillation of the eye. It is caused by slow eye movement (slow component), which is followed by fast eye movement (fast component).
- **Vertigo.** It is a sensation of spinning motion due to the dysfunction of the vestibular system. It is also accompanied by vegetative symptoms.
- **Dizziness.** An uncertain sensation of lightheadedness, or unsteadiness without the sensation of spinning motion.

Characterization of the spontaneous and gaze-evoked nystagmus

- Based on the **pathophysiology** nystagmus maybe
 - physiological (e.g., optokinetic nystagmus), or
 - pathological (vestibular, brainstem, cerebellar or retinal impairment, or drug-induced)
- **Based on the development**
 - hereditary (congenital) or
 - acquired
 - **central** or
 - **peripheral:** lesion in either inner ear or the vestibulocochlear nerve
- **Based on the appearance**
 - **Spontaneous nystagmus.** It can be observed when the patient is looking forward to rest.
 - **Provoked nystagmus.** Nystagmus cannot be observed spontaneously, but it can be provoked by gaze or other tests.
 - **Gaze-evoked nystagmus.** Nystagmus cannot be observed spontaneously (during looking forward), but it can be observed if the patient looks in one direction.
- **Direction and degrees of nystagmus**
 - The direction of nystagmus can be horizontal, vertical, rotatory, or any combination of them.
 - The direction of the nystagmus is named after the quick component.
 - **Pendular nystagmus.** If the two-directional movements are of equal velocity. It is usually central (mainly cerebellar).
 - **The direction-changing nystagmus** or bidirectional nystagmus changes its direction while looking at the other direction. E.g., if the patient looks right, the direction of nystagmus is right, if the patient looks left, the direction of nystagmus is left. It is usually of central origin.
 - **The first-degree nystagmus** is present only when looking at the direction of the quick component.
 - **Second-degree nystagmus** is present when looking at the direction of the quick component and when looking straight ahead.

- **Third-degree nystagmus** is present when looking at the direction of the quick component, when looking straight ahead, and when looking at the direction of the slow component.
- Drugs, narcotics, alcohol, or posterior fossa space-occupying lesions also have to be considered in the background of combined nystagmus.

Clinical methods for the examination of vestibular symptoms

Examination of the fixation

- The peripheral nystagmus is inhibited by the visual fixation and intensified by the inhibition of the visual fixation.
- The fixation inhibits only the peripheral nystagmus; therefore nystagmus stopped or decreased by fixation is one of the most reliable signs of the peripheral localization in vertigo.
 - **Frenzel's glasses** are the best for inhibition of fixation because the glasses inhibit the patient's fixation, and the examiner can see the patient's eyes magnified.
 - **Pupil lamp** can also be used: ask the patient to cover one of his eyes. Illuminate the other eye with the lamp. The point of light reflected on the cornea helps to observe the nystagmus.
 - **An ophthalmoscope** may also be used: Ask the patient to cover one of his eyes. Observe the nystagmus by the movements of the fundus. Be aware of the fact that the movement observed at the opposite "hemisphere" of the eye is in the opposite direction of the movement evaluated by the naked eye.

Examination of the optokinetic nystagmus

- It is a physiological form of nystagmus. The patient is looking at a moving object, e.g., a spinning, striped drum. The eye follows the movement, then quickly corrects. It can also be elicited by turning the patient round. The vestibuloocular reflex aims to keep the object on the fovea. Its presence is not examined routinely, but its examination may be helpful in the case of psychogenic "blindness".

Dix-Hallpike maneuver (or Nylen-Bárány test)

- This test is used for the examination of benign paroxysmal positional vertigo. The patient is sitting on the bed. Turn the patient's head in a 45-degree angle to one side. Thereafter fix the patient's head with your hands. Lay him back quickly in such a way that his head should hang down from the examination table by about 45 degrees. If it is impossible to hang the patient's head down from the examination table because of the arrangement of the furniture in the consulting room, place a pillow in the height of the patient's shoulders. In this way, his head will hang down from the pillow while laid back.
- In the positive case, the patient complains of vertigo within some seconds, and the examiner observes vertical rotatory nystagmus, which stops spontaneously.

Halmágyi head impulse test

- This test is appropriate for evaluating the vestibuloocular reflex and detection of peripheral vestibular lesions (lateral canal of the inner ear or vestibulocochlear nerve).
- Hold the patient's head in your hands, and tilt it approximately 30 degrees forward. Ask the patient to focus on the root of your nose, and try to fix his gaze on it during tilting his head. Turn the patient's head quickly approximately 15 degrees to the right side and observe, whether he can fix his gaze on your forehead. Repeat the maneuver in the other direction. If the results are ambiguous, repeat the test several times.
- Normally the patient can fix the examiner during the whole procedure.
- Halmágyi test is positive in the case of peripheral syndromes
 - In the case of a unilateral peripheral lesion, if the patient's head is turned towards the affected side his eyes "turn away" which is followed by a saccade-like correction.

- The Halmágyi test is usually negative in the case of central vestibular syndromes. However, there are some exceptions:
 - The Halmágyi test may be positive in the case of certain central damages (e.g., AICA infarction, which supplies the inner ear), but in this case, it is accompanied by hearing impairment as well.

Alternating cover test

- This test is appropriate for the detection of skew deviation.
- The patient is sitting in front of you fixing on your nose. Cover one of the patient's eyes, and suddenly pull the cover to the other eye. Check the uncovered eye, whether a corrective saccade can be seen or not.
- If there is no correction movement, the test is negative. If there is a correction, it means that skew deviation is present.
- The specificity of skew deviation is 98% for central vestibular lesions.

HINTS, head impulse test, nystagmus, skew deviation test

- It is the combination of Halmágyi, nystagmus, and skew deviation tests (the English name "HINTS" is an acronym from the words of Head-Impulse Test, Nystagmus and Test of Skew deviation). In the case of central vestibular symptoms, at least one of the three tests refers to central origin, i.e. it has 100% sensitivity. Therefore, HINTS is more sensitive than a diffusion MRI, and it can be carried out within 1 minute at the bedside.

Bárány test

- The patient is either sitting or standing. Ask the patient to touch your index finger, which is at arm's length. Thereafter, ask the patient to close his eyes, put his hands on his lap or next to his body, and try to place his hands back to the original position with closed eyes. If the test is positive, both fingers deviate towards one single direction at nearly the same extent (lateralization).

Romberg test

- Ask the patient to stand erect with feet together and eyes closed. Romberg test is positive if the patient sways or falls, or you can observe trunk ataxia. Stand close by as a precaution to prevent the patient from falling over and hurting himself.
- **Sharpened Romberg test.** Ask the subject to stand and close his eyes and place his right foot in front of his left foot in a heel to toe position. Observe whether the patient sways or falls, or whether there is trunk ataxia. Thereafter, ask the patient again to place his left foot in front of his right foot in a heel to toe position with closed eyes. In the pathological case, the patient sways to the same side independently from the fact, which foot is in front of the other. In psychogenic cases, the patient often sways to different sides depending on whether the right or left foot is in front.

Blind walking test

- Ask the subject to stand and close his eyes and go to a target at 5m distance. Normally he keeps the direction, but if he deviates, the test is positive. Stand close by as a precaution to prevent the patient from falling over and hurting himself.

Unterberger test (also known as Fukuda test)

- Patients are asked to walk in place for 30 seconds, whereas the patient's eyes should be closed and the room must be quiet. The goal is to remove any stimuli that a patient could use for orientation. It is considered positive if the patient starts to rotate. Examiners should be ready to prevent injuries if the patient begins to fall.

Tandem gait test (Heel-to-toe test)

- Ask the patient to walk heel-to-toe in a straight line. In a pathological case, he loses his balance. Stand close by as a precaution to prevent the patient from falling over and hurting himself.

Caloric testing

- First of all, make sure that the patient's eardrums are intact.
- Pour 20-50 ml cold water into the outer ear canal.
- Normally the eyes deviate towards the stimulus and then turn to the other direction with a quick nystagmic jerk (i.e. the nystagmus as opposed to the direction of the stimulus).
- Pathological: if it cannot be elicited, or a dysconjugate gaze.

Interpretation of the results

Normal condition

- Neither spontaneous nor gaze-evoked nystagmus can be observed.
- Physiological nystagmus (e.g., evoked by optokinetic or caloric testing) is normal, the eyes are not dysconjugate.
- Some transitional horizontal nystagmic jerks may be normal in the marginal position.
- The gaze-paretic nystagmus may be a normal phenomenon, especially in strabismus (this is the only type of direction-changing nystagmus, which does not refer to acute central lesions).

Pathological nystagmus

- The most important is to decide, whether central or peripheral causes are in the background of the nystagmus (**Table 1.**).

Peripheral nystagmus	Central nystagmus
Unidirectional, the quick component is contralateral to the lesion	It may be both unilateral or bilateral
Changing the direction of the gaze does not influence the direction of the nystagmus	Changing the direction of the gaze can influence the direction of the nystagmus (bidirectional, multidirectional)
It is accompanied by severe vertigo or emesis	It can be accompanied by milder vegetative symptoms
When the patient looks in the direction of the quick component, the amplitude may increase	The gaze-evoked nystagmus is often central (except for gaze-paretic nystagmus)
It can have multi-component (horizontal, rotatory, or vertical)	The pure vertical or pure rotatory nystagmus is usually central
It is reduced by fixation	It is not reduced by fixation

Table 1. Differentiation of the peripheral and central nystagmus.

Harmonic and disharmonic vestibular syndromes

- Harmonic vestibular syndrome = Peripheral vestibular syndrome
- Disharmonic vestibular syndrome = Central vestibular syndrome
- Differentiation of the peripheral and central vestibular syndromes is usually based on the clinical symptoms (**Table 2.**).

	Peripheral = Harmonic vestibular syndrome	Central = Disharmonic vestibular syndrome
Nystagmus	It is contralateral to the site of the lesion	It is ipsilateral to the site of the lesion
Bárány test	Directed toward the slow component	Directed toward the quick component
Romberg test	Directed toward the slow component	Directed toward the quick component
Blind walking test	Directed toward the slow component	Directed toward the quick component
Central symptoms	None	Mostly other symptoms of cerebellar, pyramidal, or brainstem lesions
Summary	Nystagmus is contralateral compared to the results of the other lateralization tests	Nystagmus is ipsilateral compared to the results of the other lateralization tests

Table 2. Differentiation of the peripheral and central vestibular syndromes.

Vestibular neuronitis

Vertigo develops gradually (not ictal, usually over several hours). It is usually spinning-like. Vestibular symptoms are seldom accompanied by hearing disturbances in the case of neuronitis. Harmonic vestibular symptoms are characteristic, nystagmus is contralateral, and leaning is ipsilateral to the lesion. Skew deviation and direction-changing nystagmus are never present in this disease; the Halmágyi test is positive in 85% of the cases.

AICA infarction

The anterior inferior cerebellar artery (AICA) emerges from the caudal third of the basilar artery. The distal branch of the AICA supplies the inner ear. This is the cause of the mixture of the peripheral and central symptoms observable during the development of the infarction of the inner ear. In the case of its blockade of AICA, vertigo (98%) and central eye movement symptoms (96%) can be observed. One of the symptoms of skew deviation, negative Halmágyi test, and direction-changing nystagmus is present in 100%.

In about half of the cases, hearing impairment also develops. In these cases, the Halmágyi test is positive and there is no skew deviation. Sometimes a sudden hearing impairment may be the only symptom of AICA infarction.

PICA infarction

Ischemia or infarction at the area of the posterior inferior cerebellar artery (PICA) always results in symptoms of an acute disharmonic vestibular syndrome.

In PICA territory infarction, a sudden onset of vertigo and leaning towards any side can be observed, but the Halmágyi test is negative. The spontaneous nystagmus is direction changing, or gaze-evoked unidirectional nystagmus appears. The postural instability is severe; patients are unable to walk without help. A skew deviation can be observed in 20% of the cases, accompanying brainstem symptoms appear in 30%. The identification of the disease is hindered by the fact that other cerebellar symptoms are very rare and very discreet or missing. Mild limb ataxia may be present. The danger of the disease is the cerebellar space-occupying edema, which develops in about 30%.

Superior cerebellar artery (SCA) infarction












Its characteristics include suddenly developing severe gait and limb ataxia, and slurred speech. It is accompanied by dizziness in half of the cases. Sometimes nausea without dizziness may be the first symptom. It is accompanied by headache in 40%, by brainstem symptoms in 50%, and by limb ataxia in 70% of the cases.

Mostly a cardiac embolism can be found in the background. The disturbance of the eye movements can be seen in about half of the cases as direction-changing nystagmus. (One of the groups of skew deviation, negative Halmágyi test, and direction-changing nystagmus is present in 100% of the cases.)

Benign Paroxysmal Positional Vertigo (BPPV)

The BPPV is the most common among the diseases accompanied by spinning-like vertigo. It is paroxysmal vertigo provoked by a sudden movement of the head or change of posture. The Dix-Hallpike and Halmágyi tests are positive. The alternating cover test is negative. There is no hearing disturbance. The vertigo is accompanied by nystagmus and significant vegetative symptoms. The symptoms begin after the changing of posture with a latency period, and they cease continuously and relatively quickly if the head remains at rest. Other central symptoms cannot be observed.

Useful videos related to the neurological examination of the vestibular system

-  Optokineitic nystagmus: <https://www.youtube.com/watch?v=LInm9cZcHyk>
-  Caloric testing: https://www.youtube.com/watch?v=liE0_AKGIWA
-  Dix-Hallpike maneuver: <https://www.youtube.com/watch?v=wgW0muB1VFY>
-  Abnormal Dix-Hallpike maneuver: <https://www.youtube.com/watch?v=7ePecb9azS4>
-  Epley maneuver: <https://www.youtube.com/watch?v=59EIKztATiw>
-  Positive head impulse test: <https://www.youtube.com/watch?v=Wh2oifgbC3I>
-  Cover test: <https://www.youtube.com/watch?v=Wf8DGL7WE8U>
-  HINTS test: <https://www.youtube.com/watch?v=1q-VTKPweuk>
-  Romberg test: <https://www.youtube.com/watch?v=H8VbKdRS-hg>
-  Sharpened Romberg test: <https://www.youtube.com/watch?v=NS6XtWfbqjc>
-  Positive Uterberger test: <https://www.youtube.com/watch?v=ljGJbokAOXM>

Examination of the motor system

During the examination of the motor system, the size (muscular trophic), tone, and strength of the muscle are examined. However, these results should be evaluated only together with the other neurological symptoms (e.g., deep reflexes, pyramidal signs, or sensory loss).

-  Lower limb motor system exam: <https://www.youtube.com/watch?v=uQVCiB1gvKw>
-  Upper limb motor system exam: <https://www.youtube.com/watch?v=tzsUE-uuxqQ>

Muscle strength

- **Paresis.** Muscle weakness.
- **Plegia.** The most severe form of muscle weakness, no voluntary movement can be observed.

Characterization of muscle strength

The extent of the muscle weakness can be graded by the Medical Research Council Scale.

- 5: Normal muscle strength
- 4: Mild muscle weakness against resistance
- 3: Movement against gravity but not against resistance
- 2: Able to move the joints horizontally, but not against gravity (only if the limb is held against gravity).
- 1: Visible or palpable muscle contraction, which is unable to move the joint even if it is held against gravity.

- 0: No visible muscle contraction (plegia)

Examination of muscle weakness

- It is very important to differentiate if the observed weakness is due to muscle paresis, or the patient just cannot exert a force (e.g. he is too tired or he has pain).
- Determine the onset time, speed, and frequency of the weakness.
 - **Monoparesis.** Muscle weakness affecting a single limb.
 - **Hemiparesis.** Muscle weakness affecting one side of the body.
 - **Paraparesis.** Muscle weakness affecting the two lower limbs.
 - **Tetraparesis.** Muscle weakness affecting all four limbs.
 - **Faciobrachial paresis.** Muscle weakness affecting the facial muscles and the upper limb.
 - **Paresis with distal emphasis.** Distal muscle weakness is more prominent than proximal.
 - **Paresis with proximal emphasis.** Proximal muscle weakness is more prominent than distal.
- Possible causes of paresis include:
 - **Lower motor neuron lesion** (peripheral, lesion of the α -motor neuron, its axon, the neuromuscular junction, or the muscle): normal or decreased muscle tone, hyporeflexia or areflexia, atrophy, fasciculation.
 - **Upper motor neuron lesion** (central): hypotonic muscle tone may be observed in the acute phase (diaschisis), which can be followed by spasticity, hyperreflexia, or pyramidal signs.
 - **Functional (psychogenic) paresis:** It does not match the anatomical relationships. A discrepancy can be observed between the actual movements and the muscle strength detected during the examination. Muscle tone and reflexes are normal. Absence of pathological reflex. It is usually of psychiatric origin.
 - **Hoover's sign.** It is suitable for testing muscle weakness of the lower limbs of psychogenic origin. The patient is lying on his back. Place one of your hands under the heel of the patient's "weak" foot. Ask the patient to raise high his other leg (by bending in the hip), while you are trying to press it down. If the affected limb is paretic, you can feel continuous pressure with your hand. If you cannot observe pressure under the "paretic" limb, it is highly probable, that this limb is not paretic. This phenomenon explains that the patient is also raising his "weaker" limb unconsciously, because of the synergistic mirror movements.
- It is worth examining the muscle strength systematically (e.g., from the top of the body to downwards), and comparing the two sides to each other (**Table 3.**).

Examined functions	Muscles	Instruction
Cervical flexion, extension, rotation	Deep cervical muscles, sternocleidomastoid and trapezius muscles	Tilt your head forward, backward, right, and left. Turn your head to the right and left.
Shoulder abduction	Deltoid and supraspinatus muscles	Raise your arms to your side.
Shoulder adduction	Pectoral and latissimus muscles	Press your arms to your side.
Shoulder anteflexion	Deltoid muscle, biceps caput longum	Raise your arms forward.
Shoulder retroflexion	Deltoid muscle	Raise your arms backward.
Outward shoulder rotation	Teres minor and infraspinatus muscles	Turn your arm outwards bending in the elbow.
Inward shoulder rotation	Subscapularis and teres major muscles	Turn your arm inwards bending in the elbow.
Elbow flexion	Biceps muscle	Bend your arm in the elbow.
Elbow extension	Triceps muscle	Extend your arms.

Wrist flexion	Forearm flexor muscles	Bend your wrists.
Wrist extension	Forearm extensor muscles	Bend your wrists backward.
Supination	Supinator muscles	Turn your palms upward.
Pronation	Pronator teres muscles	Turn your palms downward.
Finger flexion	Superficial and deep finger flexors	Grasp my hands.
Finger extension	Superficial and deep finger extensors	Open your hands and stretch your fingers.
Finger abduction	Dorsal interosseous muscles	Spread your fingers apart.
Finger adduction	Ventral interosseous muscles	Close your straightened fingers together.
Thumb abduction	Abductor pollicis muscles	Spread your thumb apart from the other fingers.
Thumb adduction	Adductor pollicis muscles	Press your thumb to your index finger.
Thumb opposition	Opponent pollicis muscles	Touch your palm with your thumb.
Hip anteversion (flexion)	Iliopsoas muscles	Raise your leg. (The patient should be lying in supine position)
Hip retroversion (extension)	Gluteus maximus muscle	Raise your leg backward. (The patient should be lying in a prone position.)
Hip abduction	Gluteus medius muscle	Lift your leg to the side.
Hip adduction	Thigh adductor muscles	Move your leg inwards in the hip.
Knee flexion	Biceps femoris, semitendinosus, and semimembranosus muscles	Bend your knee.
Knee extension	Quadriceps femoris muscle	Extend your knee.
Foot dorsiflexion	Tibialis anterior and toe extensor muscles	Stretch your foot backward as you would stand on heels.
Foot plantarflexion	Triceps surae and toe flexors muscles	Stretch your foot forward as you would walk on toes.

Table 3. The main routinely examined muscle groups.

Latent paresis tests

Certain types of mild pareses can be observed with the help of latent paresis tests. If you ask the patient to hold his limbs in a certain position, the paretic limbs get easily tired, and therefore you may observe characteristic symptoms:

- **Pronator drift sign.** It is the latent paresis test of the upper limbs. Ask the patient to close his eyes. If he is sitting, ask him to stretch out with palms upwards in such a manner that they will be parallel, and separate his fingers. If he is lying on his back, ask him to stretch out his arms at a 45-degree angle with palms upwards and separated fingers. Normally the patient can hold his arms stable. In the case of paresis, the affected limb becomes drifted and pronated. If the affected limb is only drifting, but not pronating, it suggests the possibility of functional origin (functional paresis).
- **Mingazzini's sign.** The patient is lying on his back. Ask him to close his eyes. Bend both legs in hip and knees in 90-90 degree angles. The legs should be parallel and not touching each other. If the test is positive, the affected leg is drifting.
- **Barre's sign.** The patient is lying in a prone position. His knees are bent at a 45-degree angle. If the paretic leg is drifting, the test is positive.

Tests to detect even minimal leg weakness

- Examination of the strength of dorsiflexion: Ask the patient to walk on heels.
- Examination of the strength of plantarflexion: Ask the patient to walk on toes. After this, ask him to stand on tiptoe ten times. This test can be carried out on one or both legs.

- Examination of the gluteal muscles: Ask the patient to crouch down, and stand up again. Normally he can stand up without clinging. If the patient has to lean on his thighs by his arms to be able to stand up it is called **Gowers' sign**.



Pronator drift sign: <https://www.youtube.com/watch?v=o8zkr3tmszQ>



Mingazzini sign: <https://www.youtube.com/watch?v=bz9d7fzTEGg>



Gower's sign: <https://www.youtube.com/watch?v=fwMRWrSVxVw>

Muscle tone

The muscle tone means the resistance of the muscle to passive movements. The normal constriction of the muscles is in the background of this phenomenon.

Examination of muscle tone

- Before the examination, ask the patient to sit or lie down and relax his muscles.
- In the case of upper limbs, observe the simultaneous bending and stretching of the elbow and wrist joints.
- In the case of lower limbs, observe the simultaneous bending and stretching of the hip and knee joints.
- It is worth performing these movements both slowly (the rigidity can be better observed) and quickly (the spasticity can be better observed).
- The muscle tone of the two sides should be examined consecutively and compared.

Interpretation of the results

- **Normotonia.** Only minimal resistance can be observed. The full range of motion of passive joint movements is available.
- **Hypotonia.** Decreased muscle tone.
- **Flaccid hypotonia.** Seriously decreased muscle tone. If you shake passively the patient's limb, the distal parts swing unimpededly.
- **Spasticity.** Increased muscle tone affecting one (flexor or extensor) muscle group. Spasticity is speed-dependent and can be overcome. At the beginning of the movement it is more expressed, but in quick passive movement, the tone can suddenly decrease.
 - **Wernicke-Mann spasticity.** The tone of the flexors is spastic in the upper limbs, while the tone of the extensors is spastic in the lower limbs. The Wernicke-Mann spasticity is usually unilateral. In the background, the lesion of the contralateral premotor and supplementer areas, their connections, or the corticospinal and reticulospinal pathways can be found. It is worth mentioning that the sole lesion of the primary motor cortex does not necessarily lead to spasticity without the impairment of premotor areas.
 - **Decorticate spasticity.** It is one characteristic form of bilateral tetraspasticity. It is the symmetrical increased muscle tone of flexors of the upper limbs, and symmetrical increased muscle tone of extensors of the lower limbs due to the extensive bilateral destruction of the cortex or white matter.
 - **Decerebrate spasticity.** Increased muscle tone. of extensors (spasticity) in both the upper and lower limbs. It is characteristic in upper motor neuron lesion at the level of the brainstem.
- **Rigidity.** The tone of both the flexors and extensors are increased. It can be examined most effectively by slow, passive movements. The rigidity does not depend on the speed, it is always steady.

- **Provoked rigidity.** The rigidity cannot be observed spontaneously, but during rhythmic movements of the contralateral limbs (e.g., by continuous opening and clenching of the fist), mild rigidity can be observed. These provoking mirror movements are also named as Froment-maneuver.
- **Paratonia (gegenhalten)** is a type of increased muscle tone characteristic of dementia. The tone of the flexor and extensor muscles is increased, but it is not constant, it may suddenly cease.

Phenomena reminding of increased muscle tone

- **Cogwheel phenomenon.** It is an intermittent resistance observable in resting tremor. While the passive movement of the limb is opposite to the direction of the trembling, you can experience increased resistance. When the direction of the passive movement of the limb is corresponding to the direction of the trembling, the resistance is decreased. Tremor is a sinusoidal movement, and therefore if you move the limb with rest tremor passively and slowly, you will have a feeling of moving a cogwheel.
- **Myotonia.** The relaxation of the activated muscle is delayed, which reminds to an increased muscle tone.
- **Dystonia.** It is an involuntary agonist and antagonist muscle contraction, which results in hyperkineses showing repetitive patterns or abnormal posture.

Muscular trophy

The muscle mass (muscular trophy) can present useful information in low motor neuron lesions. The muscular trophy can be evaluated by inspection, palpation, and objective measurement of the limb circumference.

Because the most common peripheral neurological diseases are usually distal, the evaluation of the trophy of small hand muscles and small foot muscles is very important. Hypotrophy of the small hand muscles can already be observed when the patient still does not observe any limb weakness during everyday activities.

- **Normotrophy.** Normal muscle size.
- **Hypotrophy.** Decreased muscle size.
- **Atrophy.** Severely decreased muscle size.
- **Dystrophy.** Although the muscle cells are lost, the muscle size appears to be normal or larger than normal. However, it is caused by the increased volume of connective tissue.
- **Inactivity atrophy (disuse atrophy).** Atrophy develops because the muscles are not used (e.g., due to a paresis following a stroke), it has no peripheral neural origin.

In the case of muscle atrophy, always examine whether **fasciculation** is present or not (the muscle contractions elicited by the spontaneous depolarization of the lower motor neuron are unable to induce active movement, but can be detected by EMG or the naked eye on the surface of the skin or the tongue). It requires long-term inspection. Most easily detected by the observation of the contour of the skin at the height of the limb.

Myokymia may mimic symptoms of a fasciculation. It is the involuntary, local jerk of the striated muscle, which is unable to induce joint movement. A typical example is the jerk of the lower eyelid caused by fatigue, lack of sleep, or excessive caffeine intake.

Reflexes

In this chapter, we review the tendon reflexes (deep reflexes), superficial, and pathological reflexes.

Tendon reflexes (deep reflexes)

Tendon reflexes are considered to be physiological reflexes. They are monosynaptic reflexes, which terminate in the spinal cord. The thick myelin fibers are responsible for the afferent part, while the lower motor neurons build up the efferent arc of the reflex. Therefore, we can say in general that decreased reflex

response can result from a lesion of both the thick myelinated sensory fibers and the α -motor neurons. Increased and brisk reflexes refer to diseases of the upper motor neurons.

Important advice for eliciting and evaluating reflexes:

- Each striated muscle has its tendon reflex, but in the clinical practice, we examine only the radial, biceps, triceps, patellar, and Achilles reflexes. In special cases, the examination of the masseter reflex may be necessary.
- Most of the tendon reflexes can be elicited in both sitting and lying positions.
- Before hitting with the reflex hammer, it is worth palpating the tendon by your hands.
- Ask the patient to relax. It is worth placing the investigated joint into a mid-position (not completely extended and not completely flexed position).
- Swing the reflex hammer briskly, not just touch the patient's skin.
- The reflex response can be either the jerk of the limb or the constriction of the affected muscles. Normally the responses are moderately brisk and symmetrical.
- Always examine the same reflex subsequently on both sides, because hereby the asymmetry is much more observable. It is important to highlight that the bending of the joints and the speed of the hitting should be the same on both sides. If you do not elicit the tendon reflex with symmetrical force, you may experience asymmetric reflex responses even in healthy individuals.
- **Hyporeflexia.** Decreased reflex response.
- **Areflexia.** Absent reflex response.
 - The importance of hyporeflexia and hyperreflexia can be evaluated only after the complete neurological physical examination.
 - The bilateral decrease or loss of Achilles and brachioradialis reflexes may be normal above the age of 60, if it is not accompanied by other neurological symptoms, and the presence of polyneuropathy can be excluded.
 - A unilateral loss of reflexes is always pathological.
 - Before you consider a reflex to be missing, repeat it several times, and use enhancing maneuvers as well.
 - **Jendrassik-maneuver (reinforcement).** By using this maneuver, the amplitude of the reflex response can be amplified. Ask the patient to flex both sets of fingers into a hook-like form, interlock those sets of fingers together, and try to pull them away.
- A **reflex asymmetry** can be considered pathological if it can be reproduced several times.
- **Brisk reflex.** A reflex response, which is greater than normal, is often accompanied by pyramidal signs.
- **Increased reflex.** The reflexogenic zone is increased. E.g., in the case of increased patellar reflex, the reflex response can be elicited by hitting the upper third of the tibia, while normally it is not possible.

 **Full reflex examination:** <https://www.youtube.com/watch?v=HMzKBg9vIXQ>

Radial reflex (brachioradial reflex)

The patient is lying on his back. Ask him to relax. Bend the arms in a 90-degree angle symmetrically, while the patient's elbow is on the examination table, and his hands are on his abdomen. If you are right-handed, place your left hand with palms upward under the patient's fingers, and hit gently but firmly the distal, radial part of the forearm with the reflex hammer. Examine the two sides after each other to be able to notice asymmetry. The reflex arc terminates in the C₅₋₆ segments.

- **Normal.** Forearm flexion.
- **Brisk.** Flexion of the elbow and/or the fingers. It does not always mean the pyramidal lesion, because for example in anxious persons brisk radial reflex may be normal.

Biceps reflex

The patient is lying on his back. Ask him to relax. Bend the arms at a 90-degree angle symmetrically, while the patient's elbow is on the examination table, and his hands are on his abdomen. If you are right-handed, place your left finger to the patient's biceps tendon, and hit gently but firmly your finger with the reflex hammer. Examine the two sides after each other to be able to notice asymmetry. The reflex arc terminates in the C₅₋₆ segments.

- **Normal.** Elbow flexion.
- **Brisk.** More expressed flexion of the elbow and/or more extended reflexogenic zone than normal.

Triceps reflex

The patient is lying on his back. Ask him to relax. Bend the arms in a 90-degree angle symmetrically, while the patient's elbow on his abdomen. Determine the position of the triceps tendon 1-2 cm above the elbow, and hit gently but firmly this point with the reflex hammer. Examine the two sides after each other to be able to notice asymmetry. The reflex arc terminates in the C₆₋₇ segments.

- **Normal.** Elbow extension.
- **Brisk.** More expressed elbow extension than normal.

Patella reflex

The patient is lying on his back. Ask him to relax. If you are right-handed, place your left arm under the patient's knee in such a position that the knee is slightly bent, but the patient's heel is still on the examination table. Determine the position of the quadriceps femoris muscle-tendon, and hit gently but firmly this point with the reflex hammer. Examine the two sides after each other to be able to notice asymmetry. The reflex arc terminates in the L₂₋₄ segments.

- **Normal.** Knee extension.
- **Brisk.** More expressed knee extension than normal. The bilateral brisk patellar reflex may also be observed in anxiety.
- **Increased.** Knee extension can be elicited by hitting the tibia (extended reflexogenic zone).

The patellar reflex can also be tested in a sitting position. In this case, the reflex response can be evaluated as follows:

- If the patient's legs are not touching the ground (e.g., it is hanging down from the examination table), you can evaluate the reflex response based on the degree of knee extension.
- If the patient's feet are touching the ground, place your left arm on the quadriceps femoris muscle, and evaluate the reflex response based on the contraction of the muscle.

Achilles reflex

The patient is lying on his back. Ask him to relax. There are two methods recommended for testing Achilles reflex:

1. Raise the patient's leg in such a position that his hip and knee will be at a 90-degree angle. If you are right-handed, place the patient's knee under your armpit, and fix it with your upper arm. Place your left hand on the plantar aspect of the patient's toes in such a position that there will be a 90-degree angle between the foot and the leg.
2. Bend the patient's knee in about a 120-degree angle, and support the patient's sole with your left hand to place the ankle-joint in a 90-degree angle.

Hit gently but firmly the Achilles tendon. The normal response is a plantarflexion. Examine the two sides after each other to be able to notice asymmetry. The reflex arc terminates in the L_{5-S₁} segments.

- **Normal.** Plantarflexion.
- **Brisk.** More explicit plantarflexion than normal.
- **Multiple responses.** One hitting elicits more spontaneous responses. It refers to the pathological processes of corticospinal pathways.

- **Absent or decreased reflex.** It can usually be observed besides polyneuropathy but decreased or missing bilateral Achilles and brachioradialis reflexes may be normal above the age of 60, if it is not accompanied by other neurological symptoms, and the presence of polyneuropathy can be excluded.

Superficial reflexes

The superficial reflexes are also called polysynaptic reflexes because interneurons modulate the processes between the afferent arc (which transmits pain stimuli) and the efferent arc (which transmits defense or consecutive movements). The main superficial reflexes are as follows:

Corneal reflex

Tactile stimulation of the cornea results in the closing of the eyelid (blinking). The ophthalmic nerve (one of the three branches of the trigeminal nerve) is responsible for the afferent arc, and the facial nerve is responsible for the efferent part of the cornea reflex. Its examination is detailed in the subchapter entitled "Examination of the trigeminal nerve".

Soft palate reflex

Unilateral tactile stimulation of the soft palate results in its constriction, and the deviation of the uvula. The trigeminal nerve (mandibular nerve) or the glossopharyngeal nerve is responsible for the afferent part depending on the location of the tactile stimulus, and the glossopharyngeal nerve and vagus nerve are responsible for the efferent part of the soft palate reflex. Its examination is detailed in the subchapter entitled "Examination of the vagus nerve".

Pharyngeal reflex

Touching of the posterior wall of the pharynx results in the constriction of the pharyngeal muscle and retching. The glossopharyngeal nerve is responsible for the afferent limb, and the vagus nerve is responsible for the efferent limb of the pharyngeal reflex. Its examination is detailed in the subchapter entitled "Examination of the vagus nerve".

Abdominal skin reflex

If you scratch on the abdominal skin from medial to the lateral side with a toothpick, this elicits the unilateral contraction of the abdominal muscles, and the umbilicus moves towards the source of the stimulation. Other authors suggest scratching on the abdominal skin from lateral to the medial side, because in this way you can prevent the unintentional pulling of the skin and the navel by the toothpick, and you can also be sure that it is the real abdominal reflex what you see. The reflex arc terminates in the thoracic segments of the spinal cord. Normally it is symmetric, but it may also be normal if it cannot be elicited at either side (e.g., obese patient with loose abdominal skin). However, the unilateral loss of the reflex is pathological.

Depending on the location of the scratching, we can distinguish:

- **Upper abdominal skin reflex.** It can be triggered by scratching the abdomen above the umbilicus.
Th₇₋₈
- **Mid-abdominal skin reflex.** It can be triggered by scratching the abdomen around the umbilicus. Th₉₋₁₀
- **Lower abdominal skin reflex.** It can be triggered by scratching the abdomen below the umbilicus.
Th₁₁₋₁₂

Plantar reflex

Plantar reflex is one of the most important superficial reflexes. The process of its testing is the same as in the case of Babinski's sign: The patient is lying on his back. Raise his ankle and hold with your other hand. Explain to the patient what you are going to do, then make a scratch on the lateral side of the sole. The reflex is switched on in the S₁₋₂ segments.

- Normal: (1.) plantarflexion: All toes bend, (2.) ticklish response.
- Only the hallux is extended, the other toes do not move. Babinski's sign refers to upper motor neuron lesion. The slow, tonic dorsiflexion of the hallux develops typically not at the beginning of scratching, but after some cm.
- The hallux is extended, the other toes spread apart: Babinski's sign, which also refers to upper motor neuron lesion.
- Triflexion response. Dorsiflexion of the foot, knee flexion, and hip flexion. It appears normally when a very strong pain is experienced on the sole (e.g., stepping into a needle). If a moderately painful stimulus (e.g., scratching the sole by toothpick) can elicit triflexion, it should be considered pathological (pyramidal sign).
- "Mute soles". The lack of any toe movement. It is pathological, and it may appear in cases of both peripheral and central lesions.

Cremaster reflex

The cremaster, bulbocavernosus, and anal reflexes are not tested routinely, however they may be important in problems of urination, urine storage, and defecation. It is suggested examining the patient in the presence of an assistant; hereby any possible problems can be avoided.

Scratching of the inner side of the thigh elicits the constriction of the ipsilateral cremaster muscle in males. Clinically it manifests in pulling up the testis on the scratched side. The reflex arc terminates in the L₁₋₂ segments.

Bulbocavernosus reflex (Osinski reflex)

Squeezing of the glans penis results in anal sphincter contraction in males. Removing an indwelled Foley catheter can elicit the same response in women. This reflex represents the preserved function of the sacral micturition center. If it is intact, the denervation of the pelvic floor muscles and the possibility of a loose sphincter muscle (L₅-S₅) can be excluded.

Anal reflex

Tactile stimulation of the perianal skin results in the contraction of the anal sphincter muscles. The reflex represents the spinal cord sacral segments S₂₋₄.

The evaluation of the resting tone of the anal sphincter muscles and the strength of the voluntary contraction by a finger is also highly important in the differential diagnosis of the neuro-urological disorders. The parasympathetic and somatic motor innervations of the rectum emerge from the S₂₋₃ segments. A decreased tone may refer to lower motor neuron lesion, and the increased tone may refer to upper motor neuron lesion.

Pathological reflexes

Pathological reflexes cannot be observed normally (except in infants), their presence usually refers to neurological injury.

Pyramidal signs

The pyramidal signs refer to the lesion of the corticospinal pathway. Although the presence of positive pyramidal signs refers to corticospinal tract dysfunction, it does not refer to the onset of the lesion. In the clinical practice, it means that e.g., a detected Babinski's sign does not necessarily indicate an acute neurological lesion, it may also a residual sign of a previous injury.

Babinski's sign and triflexion response

It is one of the most important pyramidal signs. The process of testing is the same as in the case of the plantar reflex: The patient is lying on his back. Raise the patient's ankle and hold with your other hand. Explain to the patient what you are going to do, then a scratch on the lateral side of the sole from the bottom to upwards.

- Normal response: plantarflexion, all toes bend.
- **Babinski's sign.** Only the hallux is extended, the other toes do not move. The slow, tonic dorsiflexion of the hallux develops typically not at the beginning of scratching, but after some cm.
- Babinski-like responses. The hallux is extended, the other toes spread apart. This also refers to upper motor neuron lesion.
- The hallux is extended, the other toes fan out. It also refers to upper motor neuron lesion.
- **Triflexion response.** Dorsiflexion of the foot, knee flexion, and hip flexion. It appears normally when a very strong pain is experienced on the sole (e.g., stepping into a needle). If a moderately painful stimulus (e.g., scratching the sole by toothpick) can elicit triflexion, it should be considered pathological (pyramidal sign).
- "Mute soles". The lack of any toe movement. It is pathological, and it may appear in cases of both peripheral and central lesions.

The dorsiflexion of the hallux can be elicited by several ways:

- **Chaddock's sign** is elicited by the scratching the dorsolateral side of the foot
- **Schaeffer's sign** is elicited by squeezing the Achilles tendon
- **Gordon's sign** is elicited by squeezing the triceps surae muscle
- **Oppenheim's sign** is elicited by pressing the frontal side of the tibia

Achilles clonus

- **Clonus.** It is a non-damping reflex response elicited by one single stretching stimulus. Neurophysiologists think that the appearance of the clonus is a consequence of an increased muscle tone (spasticity).
- Achilles clonus. Push the foot quickly backward with medium power; it is followed by clonus.
- It refers to a lesion of the corticospinal tract.
- In severe cases, if the patient is sitting, and his legs are placed on the ground the Achilles clonus also may appear as "tremor-like" movements of the legs.

Patella clonus

- Quadriceps clonus is elicited by the quick pushing of the patella towards the ankle with medium power.
- It refers to a lesion of the corticospinal tract.


Hoffmann's sign

The sudden pressing down of the distal phalanx of the middle finger elicits the flexion of the distal phalanx of the thumb. It may refer to a lesion of the corticospinal tract. Its bilateral presence may be normal, but the unilateral presence is pathological.

Trömner's sign

The sudden flicking of the volar aspect of the distal phalanx of the middle finger elicits the flexion of the thumb. It is less reliable than Hoffman's sign but may refer to a lesion of the corticospinal tract. Its bilateral presence may be normal, but the unilateral one is pathological.

 **Hyperreflexia, Clonus:** https://www.youtube.com/watch?v=i39Zvyhmv_A

 **Positive Babinski and normal response:** <https://www.youtube.com/watch?v=ZFu7bdbnZx8>

Frontal release signs

Frontal release signs develop mainly in cases of extensive injuries of the frontal lobe. Some of them may be physiological during infancy and early childhood period. Most of the frontal release signs are not sensitive, i.e. in certain cases, they may be present, even if there is no neurological disorder in the background.

Grasp reflex

The tactile stimulation of the volar aspect of the fingers elicits the involuntary bending of the fingers.

Rooting reflex

Touching the corner of the mouth elicits the movement of the corner of the mouth.

Bulldog reflex

The patient reflexively bites the tongue depressor placed into his mouth.

Palmomental reflex

Scratching of the thenar elicits constriction of the ipsilateral mentalis muscle. It is neither specific nor sensitive. It may appear not only in dementia but also in normal people.

Glabellar reflex

Tapping the glabella elicits the closing of the eyelids at both sides. People blink only in response to the first several taps. If the blinking persists, this is pathological and can be a sign of frontal lobe lesion. It is also often seen in people with Parkinson's disease.

Gegenhalten

If you attempt to move the limb of a patient with gegenhalten (paratonia), he will involuntarily resist regardless of the direction of the movement mimicking rigidity.

Sensory system

Without the anatomical details, the examination of the following sensory qualities is recommended:

- **Heat and pain sensation (exteroceptive, protopathic sensation).** The fibers carrying heat and pain signals cross over in the spinal cord and reach the thalamus via the contralateral spinothalamic tract (Figure 12). The tertiary fibers reach the postcentral gyrus.
- **Fine touch, pressure, vibration (epicritic sensation), and joint position sense (proprioceptive sensation).** The fibers carrying epicritic and proprioceptive sensations reach the medulla oblongata via the ipsilateral dorsal column of the spinal cord (cuneate fasciculus and gracile fasciculus), where they cross over and transmit the information to the contralateral thalamus via the medial lemniscus system (Figure 12). The tertiary fibers reach the postcentral gyrus forming the thalamocortical pathway.
- **Stereognosis, graphesthesia, two-point discrimination.** They are higher-level cortical functions. If the primary sensory systems are intact, they fundamentally refer to the parietal lobe function.

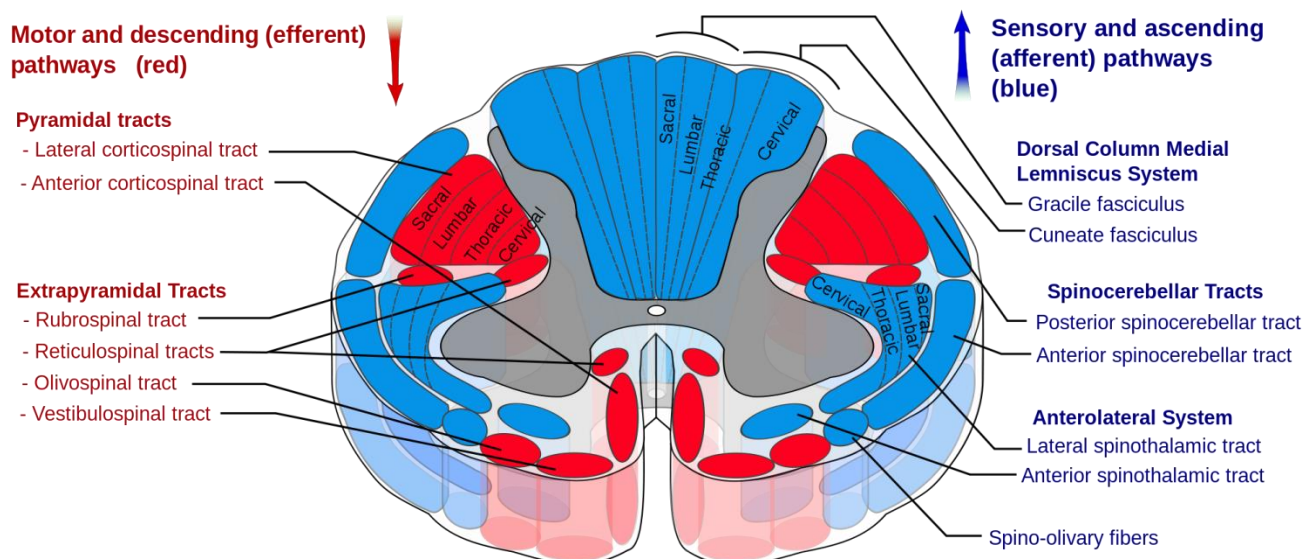


Figure 12. Main pathways of the spinal cord. Blue color indicates the ascending (afferent) pathways. It can be seen clearly that the anterolateral and dorsal column systems are anatomically separated from each other. (Source: Wikipedia.org)

During the examination of the sensory system, it is worth keeping the following rules:

- Always explain to the patient, what are you doing and what are you expecting.
- The examination is recommended to follow a logical system.
- It is suggested starting with the examination of palpation, vibration, and joint position sense because it is less inconvenient for the patient.
- Always compare the two sides for checking asymmetry
- Abnormalities observed in the sensory system always should be compared to those observed in the motor system.
- You should decide whether it is a normal or pathological perception. If it is considered pathological, you should determine the followings:
 - Is it unilateral or bilateral?
 - If it is bilateral, is it symmetric or asymmetric?
 - Is it restricted to the area of one peripheral nerve or not?
 - May it be polyneuropathy or not?
 - May it be a plexus lesion or not?
 - May it be a root lesion or not?
 - May it be a spinal cord lesion or not?
 - May it be a brainstem lesion or not?
 - May it be a hemisphere lesion or not?
- In the clinical (medical student) practice, it is enough to know the most common root lesions (C₅₋₇, L_{4-S1}), and the function of the most important peripheral nerves (median, radial, ulnar, peroneal, and femoral nerves).
- The relationship between the sensory zones of the skin and the spinal segments:
 - C₄: shoulder
 - Th₄: nipple
 - Th₁₀: navel
 - L₁: loin (Fig. 15.)
- For the major symptoms of localization diagnostics, see subchapter “Topical diagnosis”.



Examination of motor and sensory system: <https://www.youtube.com/watch?v=5ob5uJMgZOs>

Examination of fine touch

Ask the patient to close his eyes. You should gently touch the patient’s skin with a piece of cotton wool or your finger pad, and ask him whether he could feel anything. If you would like to check the compliance of the patient, you can ask him whether he could feel anything without touching him. Always compare the two sides. Always wait some seconds between two touches. Note if you experience some pathological signs and their distribution. Check also for asymmetry.

- **Tactile anesthesia.** Absence of tactile sensation.
- **Tactile hypesthesia.** Decreased tactile sensation.
- **Allodynia.** Pain due to a tactile stimulus that does not normally provoke pain.

Examination of vibration

Use a calibratable tuning fork (128 Hz). At first, place the vibrating tuning fork to the patient's forehead, and explain to him that you want to know whether he can recognize the vibration, not the tactile stimulus itself. Thereafter, ask the patient to close his eyes. Place the vibrating tuning fork on the patient's foot. Take care that you place the tuning fork to a bony area. Ask the patient whether he feels the vibration and the cessation of the vibration. Determine the smallest intensity what the patient can recognize. Repeat the test on the other side at the same point. After testing both sides, repeat the test at a more proximal site.

Depending on age, 6-8/8 vibration sensation can be considered normal. Results, worse than this, can be considered pathological. In polyneuropathy, the decrease in the vibration sensation is more expressed at the ankle than proximally (e.g., above the patella).

- **Pallhypesthesia.** Decreased vibration sensation.
- **Pallanesthesia.** Absence of vibration sensation.

Examination of the joint position sense

The easiest way to examine the joint position sense is the passive upward and downward movements of fingers and toes. At first, show the task to the patient; thereafter ask him to close his eyes. Take the patient's hallux between your thumb and index finger, and stabilize the joint with your hand. Move the distal joint gently up and down randomly. On the upper limb, the distal joint of the fourth finger is the most sensitive for checking the joint position sense. Normally the patient can feel a 1-2 mm displacement. If he cannot feel it, examine greater movements and other joints (e.g., ankle).

- **Kinanesthesia.** Absence of movement sensation.
- **Kinhypesthesia.** Decreased movement sensation.

Directional scratch test

If the patient's cooperation is not satisfying during the examination of joint position sense, or it cannot be examined due to orthopedic causes, the directional scratch test can also be used to check the function of the dorsal columns.

Use a blunt instrument (e.g., a broken tongue depressor) to make a 2 cm long scratch (e.g., right to left or bottom to upwards). Ask the patient to tell you the direction of the scratching.

Examination of pain sensation

For examination of pain sensation, use a pointed object (e.g., a toothpick) because of the maintenance of hygiene. Explain to the patient that you don't want to know whether he can recognize the tactile stimulus itself, you are interested in the fact, whether he feels the stimulus sharp or blunt. Show to the patient what you are going to do.

It is suggested starting the examination distally and moving proximally. Always compare the two sides. Note if you experience any pathological findings and their distribution as well.

You can check the patient's compliance by the random use of the pain sensation (toothpick) and touching sensation (e.g., with your finger pad).

- **Analgesia.** Absence of pain sensation.
- **Hypalgesia.** Decreased pain sensation.
- **Hyperalgesia.** Increased pain sensation to painful stimuli. In contrast, allodynia refers to pain sensation to NON-painful stimuli.

Examination of heat sensation

The heat sensation is not investigated routinely. However, certain authors prefer examining heat sensation over pain sensation, because it does not result in pain and it gives the same results.

Formally, the heat sensation is examined by test tubes filled with cold and hot water. It is important to dry the test tubes before the examination.

An exploratory examination of heat sensation can also be carried out by a reflex hammer. We can define the metal part of the hammer as a cold object, and the rubber part as a hot object.

However, the examination of the heat sensation is obligatory in the case of suspicion of spinal cord lesion (determination of the location, and suspicion of dissociated sensory loss).

- **Thermoanesthesia.** Absence of temperature sensation.
- **Thermohypesthesia.** Decreased temperature sensation.
- **Thermohyperesthesia.** Increased temperature sensation.

Examination of graphesthesia

Before the examination of graphesthesia, ask the patient to close his eyes. Draw numbers or figures (e.g., circle, square) to the patient's skin, and ask him to tell you, what was drawn to his skin.

The graphesthesia requires the intact function of the dorsal column and the related cortical areas. Consequently, decreased graphesthesia may result from both from impairment of the dorsal column and the parietal lobe.

Examination of two-point discrimination

The two-point discrimination is not examined routinely. At first, ask the patient to close his eyes. Touch his skin with two toothpicks with nearly equal pressure at the same time, and ask whether he feels it one or two., The distance, which should be perceived as two different points, is 1-2 mm on the face and hand, and 1-2 cm on the back.

The examination of two-point discrimination requires the intact function of the dorsal column and the related cortical areas. Consequently, the decreased two-point discrimination may result from both from impairment of the dorsal column and the parietal lobe.

Examination of simultaneous double stimuli

This test is not examined routinely. First, ask the patient to close his eyes. Touch the patient's skin at different body parts with two toothpicks with nearly equal pressure at the same time. This test differs from the two-point discrimination test in the fact that the stimuli are used at two different body parts at the same time. Normally the patient can differentiate, whether you used one or two stimuli. In the case of an intact primary sensory system, the inappropriate responses refer to a possible lesion of the non-dominant parietal lobe.

Differentiation of central and peripheral lesions

Differentiation of central and peripheral lesions is usually not complicated based on the following signs.

	Peripheral lesion	Central lesion
Muscle strength	Decreased	Decreased
Muscle tone	Decreased	Increased (spasticity), but it can be decreased during diaschisis
Muscular trophy	Atrophy or hypotrophy	Normal (inactivity atrophy may develop later)
Deep tendon reflexes	Decreased or missing	Brisk or increased, but it can be decreased during diaschisis
Pyramidal signs	Absent	Present, but on some occasions, they may be absent (e.g. during diaschisis)
Sensory loss	If it is present: it shows radicular, plexus, neural, and polyneuropathic distribution. There is no sensory loss in the case of selective α -motor neuron damage, and diseases of the neuromuscular junction or the muscle itself.	Classically the distribution has hemi-, para-, or tetra pattern At spinal impairment: nivou or dissociated sensory loss

Table 4. Differentiation of central and peripheral injuries.

It is important to highlight that in the case of acute central injury (e.g., stroke, spinal lesion), diaschisis may appear. In such a case, the muscle tone may decrease or become flaccid, the deep reflexes may decrease or may even be missing, and pyramidal signs cannot be observed although the central origin can be proven by imaging techniques. The diaschisis may persist from some days to weeks, and symptoms referring to classic central injuries (spasticity, deep reflexes, or pyramidal signs) develop thereafter.

In certain cases of spinal cord lesions (e.g., in the case of compressive myelopathy), spasticity may be more expressed than limb weakness. Whereas in certain cases of brain lesions, limb weakness may be more expressed than spasticity.

It may further complicate the diagnosis that certain cerebellar lesions may also result in slight paresis seeming peripheral (hypotonia, sluggish reflexes.). In such cases, if cerebellar symptoms are present, or pyramidal signs appear, it may refer to a central origin.

Phenomenological characteristics of movement disorders

Those disorders are called movement disorders, in which the function of the primary sensory and primary motor system is fundamentally intact, but the movements and coordination are damaged, or involuntary movements are present. This chapter deals with symptoms and syndromes and not with etiologies.

Tremor

Tremor. It is a rhythmic, sinusoidal, involuntary movement of the striated muscles. It is the most common movement disorder.

Clinical picture

- **Affected body parts.** Note which limb is affected by the tremor.
 - In essential tremor, postural-kinetic tremor can be observed typically at both upper limbs, however, tremor of the head (neck) and vocal cords may also appear.
 - A unilateral or asymmetrically bilateral resting tremor can be observed in Parkinson's disease: However, tremor of the lips and the lower limbs may also appear. The tremor of the head can be considered as atypia in Parkinson's disease.
- **The intensity of the tremor.** Tremor with amplitude smaller than 1 cm is clinically considered to be mild; between 1 and 3 cm, it is moderate; while above 3 cm it is severe.
- **Symmetry.** The essential tremor is rather symmetric; the Parkinsonian tremor is rather asymmetric.
- **Frequency.** It can be assessed approximately by the naked eye.
 - If it is <4 Hz, it is slow; if it is >4 Hz, it is rapid.
 - Cerebellar and Holmes' tremors are very slow (about 2 Hz).
 - The frequency of the tremor is nearly steady if it has an organic origin.
 - In the case of psychogenic tremor, if you ask the patient to make alternating movements with the contralateral limb, the tremor of another limb may take over this frequency.
- **Appearance.**
 - Rest tremor (also known as resting tremor). It appears in completely restful and undisturbed situations. It is characteristic of Parkinson's disease.
 - Postural tremor. It is a tremor appearing if the limb is held against gravity. E.g., it appears in stress (increased physiological tremor), or hyperthyroidism. Postural tremor may appear with latency in Parkinson's disease (re-emergent Parkinsonian tremor) as well.
 - Kinetic tremor. It appears during voluntary movements. E.g., it is characteristic of essential tremor.
 - Intention tremor. The amplitude is the greatest before reaching the goal in expedient movements. It can be examined by finger-to-nose or heel-to-knee maneuvers. It is frequent in cerebellar lesions, but it may also appear in essential tremor lasting for decades.

- **Task-specific tremor.** It is a tremor and/or dystonia appearing e.g., during writing or playing music. Tremor commonly can be observed besides dystonia; therefore the disease has two names: task-specific tremor or task-specific dystonia (depending on the fact which symptom is dominant). During other activities, no tremor and no dystonia can be observed.
- **Constancy.** Tremor may appear intermittently or constantly in Parkinson's disease. It can be provoked by speaking about the disease or counting. Psychogenic tremor may change or cease during making cognitive tasks (e.g., counting), or when the patient's attention is diverted.

Most common disorders

Physiological tremor (normal phenomenon), increased physiological tremor (e.g., stage fright, hyperthyroidism), essential tremor, drugs (L-thyroxine, betamimetic drugs, e.g., salbutamol, valproic acid, cholinesterase inhibitors, lithium), dystonic tremor, neuropathic tremor, cerebellar tremor, psychogenic tremor.

▶ **Examination of tremor:** <https://www.youtube.com/watch?v=myQdK6BuBws>

▶ **Examination of tremor:** <https://www.youtube.com/watch?v=SM83E11FyLc>

Parkinsonism

In the Hungarian medical terminology, parkinsonism traditionally means the secondary parkinsonism, as a disorder (etiological causes). However, in international publications, parkinsonism means a group of symptoms, which does not refer to the etiology by itself. I.e. if we say that the physical examination reveals parkinsonism, it means the presence of a special group of symptoms (and not etiology).

Parkinsonism or **akinetetic rigid syndrome.** A combination of the akinesia/bradykinesia and rigidity may be accompanied by resting tremor and postural instability which cannot be explained with any other causes. (Mark Edwards, Niall P. Quinn, Kailash Bhatia: Parkinson's Disease and Other Movement Disorders, Oxford University Press, 2008, p2).

Bradykinesia means not just slow movement but also decreased amplitude. According to its definition, bradykinesia is the combination of progressive slowing down and decrease in amplitude observed during quick alternating movements (e.g., finger tapping). It is highly important to observe a decrease in amplitude. Not only the execution of the movement is slowed down in parkinsonism, but pauses and/or decrease in amplitude can also be observed during the continuous execution of a task. On the other hand, if you investigate a patient with depression or hypothyreosis, you may experience a decrease in the speed of the movement, but it is not accompanied by a decrease in amplitude, i.e. neurologically it cannot be considered as bradykinesia.

Rigidity. It is a type of increased muscle tone, which affects the agonist and antagonist muscles at the same time. The extent of the rigidity can be evaluated based on the slow, passive movement of the main joints. At first, evaluate the rigidity without any provoking test. Examine the neck and the limbs separately. To evaluate the rigidity in the upper limbs, examine the elbow and wrist joints simultaneously. To evaluate the rigidity in the lower limbs, examine the hip and knee joints simultaneously. If rigor cannot be observed, you can use provoking tests (e.g., Froment's maneuver), in which the patient should touch his fingers together, clenching and opening of the fist, or touching the heel with one of the unexamined limbs.

Hesitation. The initiation of the movement is difficult, e.g., starting to stand up or walk.

Freezing. It is a sudden pause of walking. It is more common during turning (turning hesitation) or going through a narrow place (e.g., a doorway).

Festination. Freezing may be followed by sudden, involuntary acceleration, which is dangerous because it can result in falling.

En bloc turning. The patient turns around with multiple small 10-20 degree angle steps.

The most commonly used methods for the examination of parkinsonism

- **Examination of tremor.** The amplitude of tremor usually accelerates during counting, speaking about the disease, or walking, thus it can be observed more easily in these conditions. Examine the appearance, severity, asymmetry, and constancy of tremor.

- Examination of rigidity. It should be performed on the muscles of the neck and all four limbs separately.
- Examination of quick, alternating movements.
 - Finger tapping (continuous touching of the index finger to the thumb and spreading them again,
 - the continuous clenching and opening of the fist,
 - the continuous pronation and supination of the hand, and
 - the continuous raising of the foot and slapping back to the floor.
 - Highlight to the patient that he should perform these tasks with the highest amplitude and speed as possible. Evaluate the speed, the decrease in amplitude, and the difficulty in starting the process of freezing, if they are present. It is worth demonstrating the task before the examination.
- Examination of the posture. The posture is usually bent, stooped. Ask the patient to draw himself up.
 - Normal. Normal body posture.
 - Mild cases. The posture is bent, but the patient can draw himself up if directed so.
 - Severe cases. The patient is unable to draw himself up even if directed so.
 - Camptocormia. It is forward flexion of the spine, which is noticeable when standing or walking but disappears when lying down.
- Examination of gait. Short, narrow-based steps, pauses during turning around, simultaneous movements of the arms (synkinesis) are missing.
- Postural instability. The patient is standing with open eyes; his feet are comfortably apart. After a warning, pull him back by his shoulders.
 - Normally he can regain the posture with 1-2 steps.
 - If he needs more steps, or help to be able to regain his balance, it is considered abnormal.

Most common disorders

In the background of parkinsonism, the following disorders may be found:

- Parkinson's disease,
- Parkinson-plus syndromes (e.g., multiple-system atrophy, progressive supranuclear palsy, Lewy body dementia, corticobasal syndrome), and
- secondary parkinsonism (e.g., hydrocephalus, head injury, previous encephalitis, Wilson's disease, frontal tumor).

▶▶ **Symptoms of PD in On and OFF state:** <https://www.youtube.com/watch?v=sf1N0Zf5lqA>

▶▶ **Hypokinesia:** https://www.youtube.com/watch?v=C1euxtf_YeU

Tic

1. **Tic**. Sudden, stereotypic, involuntary movements. The patient can suppress it to a certain degree, but it can increase internal tension. It may increase as a result of stress or being left alone.

Clinical picture

- **Simple motor tic**: movements that usually involve only one group of muscles (e.g., facial grimacing, sniffing)
- **Complex motor tic**: complex movements
- **Simple vocal tic**: almost any sound, noise, word parts, or cough
- **Complex vocal tic**: compound words, sentences. Coprolalia (involuntary utterance of obscene words)

Most common disorders

Drugs (neuroleptics), Gilles de la Tourette syndrome, Asperger syndrome, head injury, neuroacanthocytosis.

 **Motor and vocal tics:** <https://www.youtube.com/watch?v=vtSchwXxn9o>

Myoclonus

Myoclonus. It is short, involuntary twitching of a muscle or a group of muscles.

Clinical picture

- **Pathophysiology**

- Positive myoclonus: It is caused by short muscle contraction.
- Negative myoclonus: It is caused by a sudden decrease in muscle tone, which is called **asterixis**.

- **Affected body parts:** focal, multifocal, segmental, generalized


- **Appearance.** It may be continuous, may appear during activities (in this case it is not present at rest), or reflexive (e.g., elicited by sound or tactile stimuli)

- **Triggering factors:**

- cortex: It is usually provoked by movement or a stimulus; EEG may be positive; the distal muscles are more affected.
- brainstem: Bilateral, synchronous movement pattern; the elbow is usually bent, the arms are adducted to the trunk, the trunk and the head is inflection. It may be provoked by touching of the nose and the lips, or sharp sounds.
- spinal cord: It may be rhythmical, bilateral, may appear during sleeping, maybe propriospinal (it is more expressed at going to bed, usually sensitive to stimuli, and affects the muscles of the trunk as well).

Most common disorders

- Physiological, e.g., hiccups
- Epilepsy: juvenile myoclonic epilepsy
- Metabolic encephalopathy (hepatic and renal failure)
- Infections: HIV, prion
- Hypoxic brain damage
- Drugs (tricyclic antidepressants, levodopa)
- Neurodegenerative diseases (Alzheimer's disease, multisystem atrophy, corticobasal syndrome)
- Neurogenetic diseases: storage diseases, mitochondrial diseases, myoclonus dystonia
- Focal cerebral or spinal lesions (stroke, demyelination, trauma, tumor)
- Paraneoplastic syndromes

 **Myoclonus:** <https://www.youtube.com/watch?v=lofvxV7tHS0>

Dystonia

Dystonia. Sustained involuntary muscle contraction, which results in twisting, returning movements, or abnormal body posture.

Clinical picture

- **Age.** Based on the onset of the symptoms:


- <20 ages it is juvenile,
- >20 ages it is adult-onset


- **Etiology:**

- **Primary dystonia.** There is no other disease in the background, e.g., dystonia caused by mutations of DYT-1 and DYT-6 genes.
- **Dystonia-plus syndromes.** Besides dystonia, other phenomena characteristic to movement disorders (e.g., parkinsonism or myoclonus) can be observed. E.g., dopa-responsive dystonia, myoclonus-dystonia, or DYT3-„Lubag”.
- **Secondary dystonia** (e.g., Wilson's syndrome, stroke, hypoxia, dystonia caused by drugs).

- **Affected body parts:** focal, multifocal, segmental, hemidystonia, generalized

- **Appearance:** mobile (phasic) or tonic.

 **Generalizált disztónia:** <https://www.youtube.com/watch?v=ir60hREgHhs>

 **Torticollis:** <https://www.youtube.com/watch?v=MwcjdiwZT8>


Chorea and ballismus


- **Chorea** is a continuous, irregular, involuntary movement resembling dance.
- **Ballismus** is a flapping, irregular, and involuntary movement.

Recently, the common phenomenon of chorea and ballismus is also called **choreo-ballistic movements**. Chorea affects mostly the distal muscles of the limbs (for this reason, it has a dance-like character), while ballismus affects the proximal muscles (therefore it is of flapping character). In Parkinson's disease, the most common causes of choreiform movements are drug-induced.

Most common disorders

- Drug-induced (e.g., dopaminergic treatment in Parkinson's disease, amphetamine, cocaine)
- Metabolic (hyperglycemia, hypocalcemia, hyperthyroidism)
- Autoimmune (SLE, antiphospholipid syndrome, pregnancy)
- Infection (Sydenham chorea: streptococcal infections, HIV)
- Cerebrovascular (e.g., subthalamic nucleus lesion usually develops in the form of hemichorea or hemiballismus)
- Hereditary (Huntington's disease, benign hereditary chorea, neuroacanthocytosis, Wilson's disease, certain types of spinocerebellar ataxias, Leigh's disease)

 **Chorea:** https://www.youtube.com/watch?v=IJ-mSD_Y5Q4


 **Ballismus:** <https://www.youtube.com/watch?v=V6cxZa6gy6g>

Athetosis

- **Athetosis** is a slow, involuntary, twisting, or writhing movement, which mostly affects the hand or the foot.

One of the most common causes of athetosis is brain damage due to hypoxia at birth or reanimation. Athetosis developing in adults may result from injury of the thalamic nuclei (e.g., stroke, carbon dioxide poisoning).

The involuntary, slow hyperkinesia of the fingers of the outstretched arm (**pseudoathetosis**) can be observed in the case of severe sensory (e.g., polyneuropathic) lesion.

 **Athetosis:** <https://www.youtube.com/watch?v=-2ODMPVjn18>

Ataxia

Ataxia means the disturbances of voluntary movement coordination. Two types can be distinguished basically: sensory ataxia (disturbance of transmission of the proprioceptive information) and cerebellar ataxia (disturbance of the structures responsible for movement coordination).

The clinical differentiation of cerebellar and sensory ataxia is summarized in **Table 5**.

Symptom	Cerebellar ataxia	Sensory ataxia
Hypotonia	+	-
Asynergy	+	-
Dysmetria	+	-
Nystagmus	+	-
Tremor (intentional)	+	-
Positive Romberg's test	+	+
Decreased joint position sense	-	+
Decreased vibration sensation	-	+
Decreased or missing deep reflexes	- (+)	+
Closing of the eyes or darkness may increase ataxia	-	+
Main causes	<ul style="list-style-type: none"> • Toxic (alcohol) • Drug (lithium, phenytoin) • Stroke (with cerebellar localization) • Demyelination • Cerebellar metastasis • Paraneoplastic syndrome • Infection (measles) • Prion • Neurodegenerative (multiple system atrophy, spinocerebellar ataxia, Friedreich's ataxia) • Vitamin deficiency (B₁, E) • Coeliac disease 	<ul style="list-style-type: none"> • Severe polyneuropathy • CIDP (Chronic inflammatory demyelinating polyneuropathy) • Paraprotein associated neuropathy • Paraneoplastic syndrome • Dorsal column pathways are affected • Tabes dorsalis (syphilitic myelopathy) • Funicular myelosis (Vitamin B₁₂ deficiency) • Cervical myelopathy e.g., due to stenosis of the spinal canal • HIV (myelopathy)

Table 5. Differentiation of the cerebellar and sensory ataxia.

Other symptoms accompanying cerebellar ataxia are detailed in the Chapter entitled "Cerebellar symptoms".

Cerebellar symptoms

▶ Examination of cerebellar signs: <https://www.youtube.com/watch?v=WdxFoUGHc54>

▶ Abnormal cerebellar signs: <https://www.youtube.com/watch?v=dFMisBl1aM>

▶ Unilateral cerebellar signs: <https://www.youtube.com/watch?v=GkPQ1ly1D88>

Examination of the eye movements

Fixation

- **Square wave jerks** may appear during looking forward (a sudden, short-term lateral eye movement, which is followed by a quick correction).

Directed eye movements

- Pause and spontaneous nystagmus can be seen usually in directed eye movements.

Examination of saccade

- Overshoot or undershoot saccade may be present.

Vestibular symptoms

- A typical **disharmonic (central) vestibular syndrome** can be observed, which is detailed in the chapter entitled “Vertigo and examination of the vestibular symptoms”.

Spontaneous nystagmus

- The quick component of nystagmus is ipsilateral in the central lesions.
- Fixation does not influence the extent of nystagmus.

Bárány test

- Deviation of the fingers towards the side of the damage

Romberg test and sharpened Romberg test

- Swaying or falling towards the side of the damage. If the patient opens his eyes, the swaying and the trunk ataxia do not improve significantly.

Blind walking test

- The direction of the gait deviates toward the side of the damage.

Tandem gait test (Heel-to-toe test)

- Ask the patient to walk straight while he places his heels in front of toes. Leaning towards one side is pathological. Stand close by as a precaution to stop the patient from falling over and hurting himself.

Examination of speech

- Scanning speech, also known as scanning dysarthria can be observed besides brainstem lesions.

Proprioceptive symptoms

- Muscle tone: **hypotonia** can be present at the ipsilateral side
- **Latent paresis test**: the outstretched upper limb can pronate and drift at the ipsilateral side.
- Muscle strength. It may slightly be decreased at the ipsilateral side (mild **hemiparesis**). Usually, only quicker fatigue can be observed, therefore drifting and pronating can be observed in latent paresis test.
- Deep reflexes: they can be **sluggish** at the ipsilateral side.

Examination of ataxia

Finger-to-nose test

- Examine only one side at a time. The patient should sit in front of you. Place your index finger about one arm distance in front of the patient, and ask him to touch your finger then touch his nose. The patient should repeat this process several times at different speeds.
 - The action and intention tremor can be observed more easily at low speed.
 - Ataxia can be observed more easily at higher speeds.
 - While the patient is doing the task, place your finger quickly to different positions. If the patient has to touch new and new targets, mild ataxia can be noticed more easily.
 - Normally the speed and the precision are appropriate.
 - In pathological cases, very low-frequency cerebellar tremor, intention tremor, **dysmetria (overshooting or undershooting the intended position)**, or ataxia can be observed.

- In functional tremor (psychogenic) cases, the patient usually does not correct or indicate verbally the mistake, if he failed the task.

Execution of quick alternating movements

- On the upper limbs, it can be examined with the continuous finger tapping, the continuous pronation, and supination of the forearms, or the continuous touching of the index finger to the thumb and spreading them again. On the lower limbs, it can be examined with the rhythmic and continuous lifting of the foot, and with drumming with the toes. Demonstrate the task to the patient, and ask him to carry out the task as quickly as possible and with the highest possible amplitude.
 - Normal: The two sides are synchronized (**eudochokinesia**).
 - Parkinsonism: Slow, decreased amplitude, sometimes hesitation and pause (**hypokinesia, bradykinesia**).
 - Cerebellar: irregular, uncoordinated, slow alternating movements (**dysdiadochokinesia**).

Rebound test

- The assessment of the required muscle strength and the accomplishment of the quick adaptive changes are damaged. Ask the patient to bend one of his arms in the elbow, and try to hinder you to straighten it. Ask him to turn his head to the other side (to prevent him from hitting his face). Place your other hand to the patient's shoulder, and suddenly release his hand.
 - Normally the patient's arm remains in the same position (it refers to good muscle strength adaptation).
 - Pathological: The patient hit himself; he may make large movements several times.

Heel-to-knee-to-shin test

- The patient should lie on his back. Ask him to raise one of his legs, place his heel to his knee, and pull his heel along his shin. Ask him to repeat it on the other side. If there is any dysmetria or ataxia, it is pathological.

Examination of gait

- Wide-based, tottering, ataxic gait. Ataxia is not worsened by closing the eyes.
- Examine spontaneous gait, tandem gait, and blind walking as well.

Interpretation of the results

- Limb ataxia usually develops in lesions of the cerebellar hemispheres. Whereas, trunk ataxia is usually caused by lesions of the midline structures (cerebellar vermis).
- In the case of lesion of the midline structures, the tests appropriate for examining limb ataxia may be normal.
- Sensory ataxia can be caused by severe sensory impairment. Symptoms of sensory ataxia are usually worsened by closing the eyes, and pseudoathetosis may also appear (abnormal hyperkinesia of the outstretched arms).
- The execution of quick alternating movements is also damaged in **parkinsonism**: slowness, freezing, hesitation, and reduction in the amplitude can be observed.
- The execution of quick alternating movements is also damaged in **hemiparesis**: slow, but not irregular. This cannot be considered as a cerebellar symptom.
- **Charcot's triad** (intention tremor, scanning speech, and nystagmus) may appear in multiple sclerosis.

Gait abnormalities

The gait is one of the most complex neurological functions. E.g., the appearance of certain gait disturbances may refer to not only the injury of the motor, sensory, visual, and vestibular systems but may predict the patient's cognitive deterioration.

Examination of gait

- Observe the patient while he is entering into the consulting room. Is he using anything to be able to walk? Does he need any help?
- Ask the patient to sit down, pull down his shoe and socks, and pull up the leg of his trousers up to his knee.
- Ask him to stand up, and check whether he needs help or not.
- Ask him to walk at least 5 meters without any help, if it is possible. If he needs help, helps the patient yourself, so you can evaluate, how much he leans on you, and how much help he needs.
- Observe the initiation of gait (e.g. is there any hesitation).
- Observe the speed of the walk and the distance between the legs (narrow or broad-based gait).
- Ask the patient to turn around. Observe, whether he can turn around with one step or needs more. Is there any sudden pause during the process?
- Observe the posture (e.g. leaning forward), and the simultaneous movements of the hands (**synkinesis**).
- Observe the movements of the legs, knees, and feet.
- **Blind gait.** Ask the patient to close his eyes. Stand close by as a precaution to prevent the patient from falling over and hurting himself. Ask him to start to walk. Observe the gait pattern, speed, and any deviation during gait.
- If the patient needs a **mobility aid** for walking, check whether there is any improvement in his gait by using it. If he does not need any mobility aid for walking, and his gait is not normal, examine whether using your help may improve the gait or not.

Table 6 summarizes the major gait problems.

Type of the gait	Characteristics	Accompanying symptoms and complaints	Tests
Antalgic gait	limping, easing the painful limb during standing https://www.youtube.com/watch?v=W-S8Pk63YRE	Pain	
Steppage gait	the foot is hanging, the knee is raised high https://www.youtube.com/watch?v=1bvj9AELorc	lesion of the peroneal nerve or polyneuropathy	unable to stand on heels
Trendelenburg gait (waddling gait, myopathic gait)	the hanging of the hip is compensated by waddling movement https://www.youtube.com/watch?v=gXws-A4op-E	lesion of the gluteus medius muscle, myopathy	the patient is unable to hold his hip horizontally during standing on one foot
Spastic gait	no knee flexion, circumduction, flexion of the upper limb https://www.youtube.com/watch?v=7w-fhfdifNc	previous central palsy, symptoms of upper motor	

		neuron lesion, spasticity	
Scissoring gait (diplegic gait)	knees and thighs crossing in a scissors-like movement https://www.youtube.com/watch?v=iFen9J7XWpk	bilateral upper motor neuron lesions (e.g. cerebral palsy)	
Vestibular gait	its direction deviates during blind walking	it is accompanied by nystagmus	
Sensory ataxic gait	tottering, wide-based	sensory symptoms	it is worsened by closing the eyes
Cerebellar ataxic gait	tottering, wide-based https://www.youtube.com/watch?v=JSyLnt3rLxs	cerebellar symptoms	it is not influenced by eye-closure
Hypokinetic gait	narrow-based, slow, pauses, hesitation, lack of synkinesis https://www.youtube.com/watch?v=yhj1PktNA1c	Parkinson's disease	it is helped by outer stimuli and deteriorated by dual tasks
Dyskinetic gait	hyperkinetic movement disorder https://www.youtube.com/watch?v=PsFJkL3x10o	symptoms of dystonia, chorea, etc.	
Apraxic gait (higher-level gait disorder)	inadequate synergy, wide-based, hesitation https://www.youtube.com/watch?v=hziyFfJTrQo	frontal symptoms, dementia	execution of quick alternating movements (e.g., bicycle) is easier in bed
Psychogenic gait	bizarre https://www.youtube.com/watch?v=zJIZtob8mv0		its character is changing during dual tasks or attention diversion

Table 6. Characteristics of the major gait problems.

Examination of functions of the cortical lobe

Apraxia

We can speak about apraxia, if the patient is alert, able to understand the instructions, and his primary motor system is intact, but the planning and execution of the actions are damaged. It indicates disturbances of the higher-level cortical functions.

Ideational apraxia

The patient is unable to plan a task, e.g., he does not know how to open a closed door: enter the key, turn the key, and press the handle. Damage of the parietal lobe of the dominant hemisphere can be suspected.

Ideomotor apraxia

The patient can plan how to perform tasks, but unable to carry out them. E.g., he does not know how to pour water into a glass. Damage of the parietal lobe of the dominant hemisphere can be suspected.

Constructional apraxia

The patient can orient and act in a two-dimensional system, but he is unable to do them in a three-dimensional system. The injury of the non-dominant hemisphere is characteristic. E.g., he cannot manage an inside-out dress, draw three-dimensional objects, or build formations from building bricks according to your instructions.

Gait apraxia

The execution of the gait is damaged; the patient can move better in bed (e.g., bicycling-like movements). The gait is wide-based, which may be accompanied by hesitation. The patient is unable to carry out the steps well without help. In mild cases, he can walk properly with some help, but in more severe cases he cannot do it anymore. Damage of the frontal lobe can be suspected (e.g. dementia).

Aphasia

We can speak about **aphasia**, if the patient is alert, the primary auditory system is intact (e.g., able to hear noises), the innervation of the muscles responsible for speech is intact, and previously he was able to speak. Regardless of these, in aphasia, the patient is unable to speak and/or understand speech. It indicates disturbances of the higher-level cortical functions.

Observe:

- the spontaneous speech (continuous or not)
- the understanding of the instructions
- the ability of repetition

Broca's aphasia (motor aphasia)

The patient does not speak spontaneously or only slightly. He can understand and follow the instructions (e.g., "raise your hand", "stick out your tongue"). But he cannot repeat sentences or hardly.

It is caused by the damage of the Broca area which is responsible for motor speech and can be found in the frontal lobe of the dominant hemisphere.

It should be differentiated from the followings:

- Dysarthria. Defect of the muscles responsible for speech, or their innervation.
- Aphonia. Inability to produce voice.

Wernicke's aphasia (sensory aphasia)

The patient can speak spontaneously, but usually incorrectly (also known as jargon aphasia). He cannot understand the instructions or repeat the sentences.

It is caused by the damage of the temporal lobe of the dominant hemisphere (speech understanding center, Wernicke's center).

Global or total aphasia

The patient is unable to speak spontaneously, repeat sentences, or understand the instructions. It may be caused by damage to the cortical (frontal and temporal) structures of the dominant hemisphere or the structures which connect them.

Anomic aphasia

Defective recall of specific names of objects or other words, with intact abilities of comprehension and repetition

Agnosia

Agnosia. Even though the primary sensory, auditory, or visual systems are intact, the patient is unable to recognize stimuli. It indicates disturbances of the higher-level cortical functions.

Astereognosis (tactile agnosia)

The patient is unable to identify an object by touching, without visual input.

Autotopagnosia

The patient is unable to localize and orient different parts of his own body.

Prosopagnosia

The patient is unable to recognize faces, usually not even his own.

Visual agnosia

The patient is unable to recognize objects. It refers to lesions of the left occipital lobe and temporal lobes.

Anosognosia, neglect

It results from damage to the subdominant higher-level cortical function.

- In the case of **sensory neglect**, the patient ignores the visual, acoustic, and tactile stimuli coming from his left side. If you examine separately, the patient can recognize the stimuli from both sides, but if you examine the two sides at the same time, he ignores stimuli coming from the left.
- **Hemispatial neglect.** The patient neglects the left side of the clock.

Other gnostic disorders

Agraphia

The patient is unable to write despite the intact innervation of the dominant hand, whereas previously he could write.

Alexia

The patient is unable to understand a written text despite the intact primary visual system, whereas previously he could read.

Amusia

The patient is unable to play music or recognize familiar melodies, whereas previously he could play music.

Acalculia

The patient is unable to perform simple mathematical tasks, whereas previously he could count.

Gerstmann's Syndrome

Right-left confusion, finger agnosia, agraphia, and acalculia are caused by damage to the dominant (left) angular gyrus.

Examination of a comatose patient

Disturbances of consciousness should be classified:

- arousal („wakefulness”, ascending reticular activating system)
- awareness (cortical function)

Disorders of vigilance

Synonyms: hypnoid disorders of consciousness, alert, arousal, wakefulness

The function of the reticular formation is essential to maintain vigilance.

Torpidity, daze

It is the mildest disorder of vigilance. The patient is completely alert, but slowed down, he has troubles with focusing.

Somnolence

It is a condition similar to superficial sleeping. The patient can be awakened easily by verbal or other sensory stimuli. He may behave completely adequately as well.

Sopor

The patient can only be awakened by stronger stimuli, and his behavior is rarely completely adequate. Avoiding movements can be observed in response to pain stimuli; he may recognize his family members.

Coma

The patient cannot be awakened at all. In the case of superficial coma, superficial reflexes may be elicited (e.g., cornea reflex). In the case of a deeper coma, these reflexes cannot be elicited, and breathing becomes inadequate.

Brain death

Brain death is a special condition in which the brain is damaged irreversibly. The brain death determination is ruled by statutory provisions.

Brain death determination is carried out in three steps.

- The first step is the exclusion of the presence certain factors (e.g., poisoning, drugs, neuromuscular blockade, shock, metabolic or endocrine comas, hypothermia (under 35°C) measured rectally, certain inflammatory neurological diseases), which would make the reliable brain death determination impossible.
- If the previously mentioned factors can be excluded, the second step is to confirm the loss of brain function. Symptoms, which can prove this, are as follows:
 - Coma: Deep loss of consciousness.
 - Lack of spontaneous breathing and paralysis of the respiratory center can be confirmed by the apnea test.
 - The following brainstem reflexes are missing at both sides:
 - pupillary reflex
 - cornea reflex
 - trigeminofacial pain reaction
 - vestibuloocular reflex (by caloric testing)
 - cough reflex, pharyngeal reflex
- The third step of brain death determination is to prove the irreversibility of the missing brain functions. It can be carried out by multiple observations or instrumental analysis.

Integrative disorders of consciousness

(Synonym: awareness)

Tenebrosity

It usually develops following an epileptic seizure, but may also appear in transient global amnesia. The patient reacts slowly and does not behave adequately. Aphasia may be present.

Confusion

It is a partially or completely impaired orientation concerning place, time, and person. The patient may limitedly react to stimuli of the environment and may be accompanied by psychomotor agitation.

Delirium

It is a state accompanied by spatial and temporal confusion as well as expressed vegetative symptoms, which may be life-threatening without adequate treatment. It is often accompanied by hallucinations. Delirium usually develops quickly (within hours or days). Delirium is usually considered to be the most serious cause of confusion.

It is often caused by alcohol, tranquilizers, narcotic intoxication, or withdrawal, but it can also associate with dementia.

Persistent vegetative state

The patient's sleep-wake cycle is more or less intact, he can produce reflex responses but unable to perform conscious activities. It appears usually as an "improved state" of comatose patients. The patient's breathing is ensured by reflexes, the gaze, which is sometimes believed to be voluntary, consists only of reflexive eye movements. Neither verbal nor non-verbal communication is possible.

Minimally conscious state

It is a state similar to a persistent vegetative state, but the patient can communicate a little for a short period.

Akinetic mutism

It is a special defect of attention and impulse disturbances, which result in symptoms similar to disorders of consciousness. The patient's eyes are open; he can produce conjugated eye movements. He does not speak because of the damage of the frontal lobe (e.g., stroke in the area of the anterior cerebral artery), but he can understand his environment more or less.

Locked-in syndrome

The patient is tetraplegic and unable to speak due to a lesion of the basis of the pons. But he is usually able to communicate with his eyes (blinking). It is not a real disorder of consciousness, because consciousness is retained.

Examination of a comatose patient

The types and orders of the tests, which should be performed on a comatose patient, always depend on the clinical condition. The following list follows a didactical order.

1. Quick anamnestic data, inspection (head injury, drugs)
2. General examination
 - a. Pulse: is the circulation and its frequency maintained (shock, sepsis)?
 - b. Breathing: is the breathing maintained?
 - i. periodic breathing (Cheyne-Stokes breathing): brainstem lesion, heart failure
 - ii. slow, superficial breathing: drugs, narcotics
 - iii. quick, superficial breathing: brainstem
 - iv. quick and deep breathing: metabolic (acidosis, hyperglycemia)
 - c. Temperature (hypothermia, hyperthermia) e.g., by palpation of the skin
 - d. Skin color: sweat, pale, needle marks, rashes
 - e. Breath (alcohol, ketone, liver failure, uremia)
 - f. Abdomen: defense

3. Neurological examination

- a. Meningeal signs (it is recommended only if cervical trauma can be excluded): it may be positive in subarachnoid hemorrhage, foraminal herniation, and meningitis
- b. Fundus of the eye: papilloedema, bleeding
- c. Size of the pupil and pupillary reflex:
 - i. Unilateral, maximally dilated, does not react to light: tentorial herniation (oculomotor nerve)
 - ii. Bilateral, maximally dilated, does not react to light: brainstem lesion, herniation, atropine-like substances
 - iii. Mid-dilated fixed: mesencephalon
 - iv. Tiny, pinpoint: pons, opioids
 - v. Small, but reactive: thalamus
 - vi. Horner's syndrome: hypothalamus, brainstem, internal carotid artery dissection
 - vii. Pupil dilation, if you pinch the skin of the neck – ciliospinal reflex
- d. Position of the eyes:
 - i. conjugate deviation: ipsilateral frontal gaze center, or brainstem
 - ii. dysconjugate: injury of the oculomotor, trochlear, and abducens nerves, or brainstem
 - iii. Skew deviation: brainstem
- e. Spontaneous eye movements:
 - i. repetitive horizontal movements: ping-pong, brainstem
 - ii. downward deviation of the eyes: pons
- f. Reflex eye movements
 - i. Oculocephalic or doll's eyes reflex
 - ii. Oculovestibular reflex
- g. Corneal reflex
- h. Pharyngeal and soft palate reflexes: If the patient is intubated, examine these reflexes by the cautious moving of the tube.
- i. Muscle tone
 - i. decorticate: hemispheric
 - ii. decerebrate: brainstem
 - iii. hypotonia
- j. Muscle movements
 - i. spontaneous movements, sometimes clonic epileptic seizure
 - ii. pain-evoked movements: defense, flexion, extension, twisting
 - iii. Psychogenic: The patient's hand is dropped on his head: if the hand "accidentally" avoids the face, the suspicion of psychogenic can be confirmed.
- k. Deep reflexes (sluggish, brisk, or increased)
- l. Pyramidal signs

Glasgow Coma Scale (GCS)

The Glasgow Coma Scale is a scale elaborated to assess the severity of the coma and the potential outcome. It was elaborated to assess the recovery of traumatic brain injury patients; therefore its use is not adequate to assess the prognosis in certain neurological diseases (e.g., myasthenic crisis). The GCS has also limited applicability to children.

Best eye response (E - eye)

1. No eye-opening.
2. Eye-opening in response to pain stimulus. (A standard pain stimulus is the squeezing of the lunula, if it is ineffective, the pressure of the supraorbital or sternal areas should be tried.)
3. Eye-opening to speech. (Not to be confused with the awakening of a sleeping person; such patients receive a score of 4, not 3.)
4. Eyes opening spontaneously.

Best verbal response (V-verbal)

1. No verbal response.
2. Incomprehensible sounds.
3. Inappropriate words. (Random or exclamatory articulated speech, but no conversational exchange.)
4. Confused. (The patient responds to questions coherently but there are some disorientation and confusion.)
5. Oriented. (The patient responds coherently and appropriately to questions such as the patient's name and age, where he is and why, the year, month, etc.)

Best motor response (M-motor)

1. No motor response.
2. Extension to pain. (Decerebrate response: the abduction of arms, external rotation of shoulders, supination of forearms, the extension of wrists. The lesion affects the brainstem.)
3. Abnormal flexion to pain. (Decorticate response: adduction of arms, internal rotation of shoulders, pronation of forearms, and flexion of wrists.)
4. Flexion, withdrawal to pain. (Flexion of the elbow, supination of the forearm, and flexion of the wrist as a response to supraorbital pressure; pulls his finger away when nailbed pinched.)
5. Localizes to pain. (Purposeful movements towards painful stimuli.)
6. Obeys commands. (The patient does simple things as asked.)

Interpretation

The individual elements and the sum of the score are also important. Hence, the score is expressed in the following form: "GCS 9 = E2 V4 M3".

Evaluation of the severity of the coma:

- Major, with GCS ≤ 8 (intubation is suggested due to the risk of aspiration)
- Moderate, GCS 9–12
- Minor, GCS ≥ 13

Main causes of impaired consciousness

The possible causes can be grouped according to two main characteristics:

One is the symptomatic nature of the disorder itself, which is detected during the neurological examination. This pattern may be symmetric or non-symmetric.

Non-symmetric symptoms are those that are observed during the examination (e.g. left limb weakness in right hemisphere stroke, long trajectories, etc.).

Symmetric symptoms are present when no lateral difference is detected (e.g. bilateral longitudinal symptoms in brainstem lesions) or no neurological signs are found.

Another characteristic is the nature of the lesion. This may be structural or non-structural. In the case of structural lesions, lesions can be detected by appropriate brain imaging, whereas in the case of non-structural lesions they are absent.

Four categories can be defined based on the two main characteristics.

1. Structural, non-symmetric
2. Structural, symmetric
3. non-structural, symmetric
4. Non-structural, non-symmetric

This classification can be useful in the search for possible causes when the neurological symptomatology and imaging data are combined with other information (e.g. laboratory, toxicology, etc.).

	Symmetric	Non-symmetric
Structural	<p><u>Supratentorial</u>: bilateral ACI, ACA occlusion, SAH (in some localisations)</p> <p><u>Infratentorial</u>: infarction, haemorrhage, basilar occlusion</p>	<p><u>Supratentorial</u>: mass lesions (subdural haematoma, stroke, cerebral infarct, vasculitis, etc.), DIC, thrombocytopenic purpura</p> <p><u>Infratentorial</u>: infarct, haemorrhage</p> <p><u>Other</u>: PML, CJD, Acute encephalomyelitis some</p>
Non-structural (based on appropriate neuroimaging)	<p><u>Toxic</u>: CO, cyanide, ethylene glycol</p> <p><u>Drugs</u>: sedatives, barbiturates, alcohol, opiates</p> <p><u>Metabolic</u>: hypoxia, hypercapnia, hyper-, hyponatremia, hypoglycaemia, hyperglycaemia, hepatitis, renal failure, hypo-, hyperthermia</p> <p><u>Infectious</u>: Bacterial, viral meningitis, encephalitis (some types) postinfectious meningoencephalitis, sepsis</p> <p><u>Other</u>: postictal, global cerebral hypoperfusion (circulatory failure)</p>	<p>Perhaps the most difficult group to explain. In the case of previous structural damage (whose symptoms have been minimised or even eliminated during the course of recovery), we see the reappearance of neurological symptoms of previous damage at the bottom of some metabolic derailment (e.g. hypoglycaemia). It may also occur in postictal conditions in some cases.</p>

Topical diagnosis

Hemispheric damage

- Typical: Contralateral hemiparesis and/or hemihypalgesia.
- Cortical homunculus:
 - in the midline: lower limb;
 - area folding into the medial longitudinal fissure: pelvis;
 - lateral, convex side: torso, upper limbs, and palms of the hands;
 - around the Sylvian fossa: face and tongue (Fig. 12.).

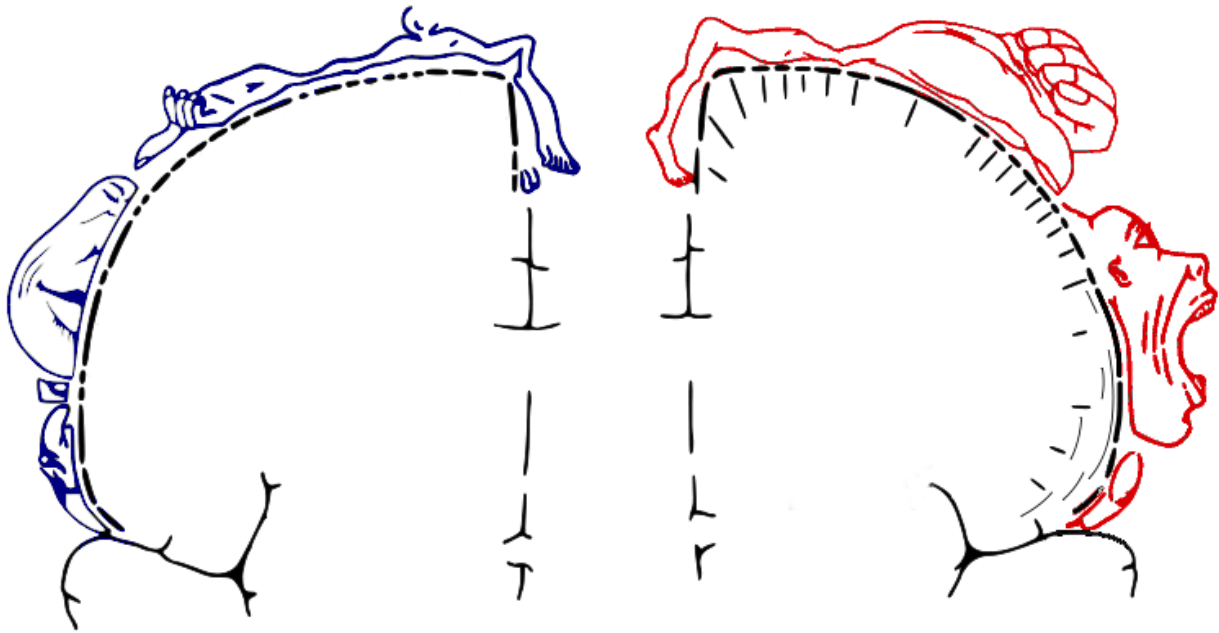


Figure 13. Sensory and motor homunculus. The cortical homunculus of the primary sensory cortex can be seen at the left side (indicated with blue) and the cortical homunculus of the primary motor cortex can be seen at the right side (indicated with red). Both the sensory and motor representation of the hands, lips, and face are disproportionately huge in comparison to the rest of the body. It is worth mentioning that the representation of the face and fingers are neighboring, which can explain the fact that the clonisation of the hands can be followed by the clonisation of the facial muscles as the epileptic seizure spreads through the motor cortex.

Area of the middle cerebral artery (MCA)

- symptoms with faciobrachial distribution (contralateral central facial nerve palsy and upper limb paresis)
- aphasia is also frequent

Area of the anterior cerebral artery (ACA)

- It can cause lower limb paresis.
- If it is bilateral (e.g., paramedian space-occupying tumors or bleeding) it can also cause paraparesis.

Area of the posterior cerebral artery (PCA)

- Homonymous visual field defects

Subcortical vs. cortical

in the case of subcortical lesion

- visual deficits are more common (because the optic tract or optic radiation are affected),
- dysarthria is more common

Lacunar damage

- It may be pure motor monoparesis
- It may be pure sensory hypalgesia affecting only one limb
- It may be pure ataxia affecting only one limb
- It may be dysarthria, dysphagia, and clumsy hand (lacunar infarction at the area of the pons, and medulla oblongata)

Special cortical areas:

- e.g., apraxia, aphasia, agnosia

Watershed (border zone) infarcts

- Areas between the ACA- MCA and MCA - PCA supplied by end arteries. Unilateral: stroke; bilateral: hypoxia and hypotension may be the cause.

Brainstem lesionsCharacteristics:

- Cranial nerves are usually affected (can have central or peripheral appearance).
- Alternating brainstem syndromes: compared to the lesion there are ipsilateral cranial nerve symptoms and contralateral limb symptoms.
- Eye movement disorder, skew deviation, nystagmus
- Cerebellar and/or vestibular symptoms
- Dysarthria, dysphagia
- Disorders of consciousness
- Respiratory and circulatory disturbances

It may be intra-axial lesion (within the brainstem) and extra-axial lesion (e.g., meningioma, aneurysm, a neuroma may cause pressure from outside).

An intra-axial brainstem lesion may cause damages clinically appearing either peripheral (if it affects the motor nucleus) or central.

The bilateral injury of the corticobulbar tracts (pseudobulbar paresis) may imitate symptoms of brainstem lesion even though it is usually caused by bilateral hemisphere damage (dysarthria, dysphagia, increased pharyngeal reflexes, or compulsive weeping).

Alternating brainstem syndromes

- ipsilateral cranial nerve symptoms and contralateral limb symptoms
- **Table 7** summarizes some important brainstem syndromes.

Syndrome	Location of the lesion	Ipsilateral symptoms	Contralateral symptoms
Benedikt's syndrome	Mesencephalon (red nucleus)	<ul style="list-style-type: none"> • oculomotor nerve palsy 	<ul style="list-style-type: none"> • Hemichorea or hemiathetosis (red nucleus) • Hemiparkinsonism (substantia nigra) • Hemihypaesthesia (medial lemniscus)
Millard–Gubler syndrome	Pons	<ul style="list-style-type: none"> • Peripheral facial nerve paralysis 	<ul style="list-style-type: none"> • Hemiparesis • Unilateral sensory loss (medial lemniscus and lateral spinothalamic tract)
Foville's syndrome	Pons	<ul style="list-style-type: none"> • Peripheral abducens nerve 	<ul style="list-style-type: none"> • Hemiparesis

Wallenberg syndrome	Lateral part of the medulla oblongata (PICA)	<ul style="list-style-type: none"> • Ipsilateral nystagmus (inferior vestibular nucleus) • Hemiataxia (Inferior cerebellar peduncle) • Ipsilateral soft palate, pharyngeal, and laryngeal paralysis (nucleus ambiguus) • Hearing loss (cochlear nerve) • Unilateral loss of pain and heat sensation (spinal trigeminal nucleus) • Horner's syndrome (central sympathetic fibers) 	<ul style="list-style-type: none"> • Hemianalgesia and thermanesthesia, dissociated sensory loss on the contralateral extremities (lateral spinothalamic tract)
Jackson's syndrome	The lower part of the medulla oblongata	<ul style="list-style-type: none"> • Peripheral hypoglossal nerve 	<ul style="list-style-type: none"> • Hemiparesis

Table 7. The main alternating brainstem syndromes.

Cerebellar lesions

- Central vestibular symptoms (nystagmus, Romberg test, Bárány test, blind gait test)
- Ataxia (non-sensory)
- Rebound phenomenon (positive rebound test)
- Dysmetria
- Dyssynergia
- Dysdiadochokinesis
- Intention tremor
- Scanning speech (scanning dysarthria)

Spinal cord injury

- No cranial nerve symptom (except for the cervical syringomyelia affecting the medulla oblongata or accessory nerve palsy)
- Sensory loss:
 - nivou (breast Th4, navel Th10, inguinal region L1)
 - dissociated sensory loss
- Motor symptoms
 - Paraparesis (Th1-S2),
 - Tetraparesis (Th1 or above),
 - but may also be hemiparesis and monoparesis (especially in the cases of partial lesions)
 - Respiratory paralysis: C4 or above
 - Acute spinal shock: flaccid paresis, which later becomes spastic
- Vegetative
 - Frequent bladder dysfunction (detrusor-sphincter dyssynergia, automatic neurogenic bladder, overflow incontinence)
 - Frequent decubitus, disorders of temperature control

Dissociated sensory loss

The epicritic and protopathic sensations are lost separately.

- Damage to the lateral spinothalamic tracts, the dorsal column is intact:
 - loss of pain and temperature sensation
 - anterior spinal syndrome, syringomyelia
- Damage to the dorsal column, the lateral spinothalamic tracts are intact
 - loss of fine touch, vibration sensation, and proprioception
 - Funicular myelosis, tabes dorsalis

Brown-Séquard's syndrome

Unilateral transection, frequently caused by an extramedullary lesion

- Unilateral spastic paralysis (lower limb monoparesis and/or hemiparesis depending on the site of the lesion)
- Peripheral symptoms may be present at the level of the lesion
- Ipsilateral loss of epicritic sensation
- Contralateral loss of temperature and pain (protopathic) sensation

Conus lesion

- Motor symptoms
 - often missing, but if the L5-S2 (epiconus) segments are also affected, a peripheral paraparesis may be present
- Sensory loss
 - Sacral (S3-S5) hypalgesia may appear (mainly perianal territories)
- Vegetative
 - Urinary retention – detrusor areflexia (non-obstructive retention or overflow incontinence), Fecal incontinence
 - Anal or bulbocavernosus reflexes may be absent
 - Sexual dysfunction (erectile dysfunction in men)

Cauda lesion

Lesion of the lumbar and sacral nerve roots (cauda equina) within the spinal canal

Usually, it develops slowly.

- Motor symptoms
 - peripheral paraparesis, which is usually asymmetric
 - patellar and Achilles reflexes may be absent
- Sensory loss
 - Sacral hypalgesia may appear, which is usually asymmetric
 - radicular radiation of pain is possible. which is usually asymmetric
- Vegetative
 - Detrusor areflexia (non-obstructive retention or overflow incontinence)
 - Fecal problems
 - Anal or bulbocavernosus reflexes may be absent
 - Sexual dysfunction

Plexus lesions

There are sensory, motor (peripheral), or vegetative symptoms according to the plexus.

Usually, the symptoms comply with those of the unilateral and peripheral injury.

The precise topographical determination of the injury is difficult because of the complex structure of the brachial plexus.

The injury of cervicobrachial plexus is most commonly due to shoulder injuries, elbow sprains, or birth trauma.

Cervical plexus

- C₁₋₄
- The main motor nerve is the phrenic nerve. The most common cause of injury is a trauma, compression, or tumor infiltration of the thoracic wall.
- Sensory nerves: the lesser occipital nerves and the cutaneous cervical nerve, which are responsible for the sensory innervation of the areas of the neck, nape, and head behind the ear.

Brachial plexus

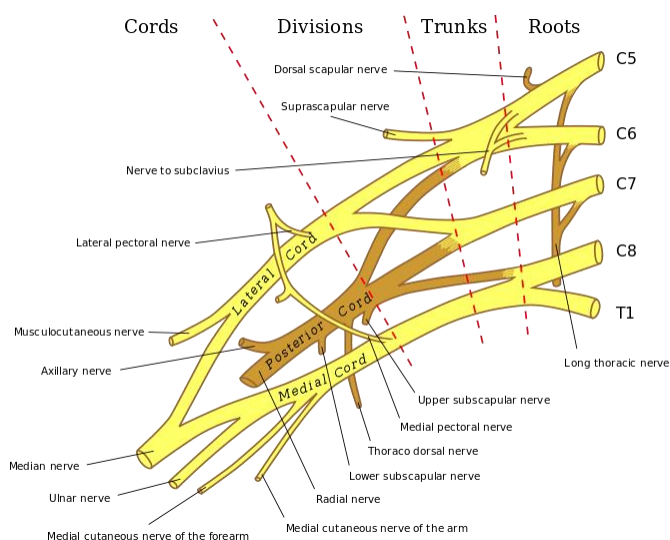
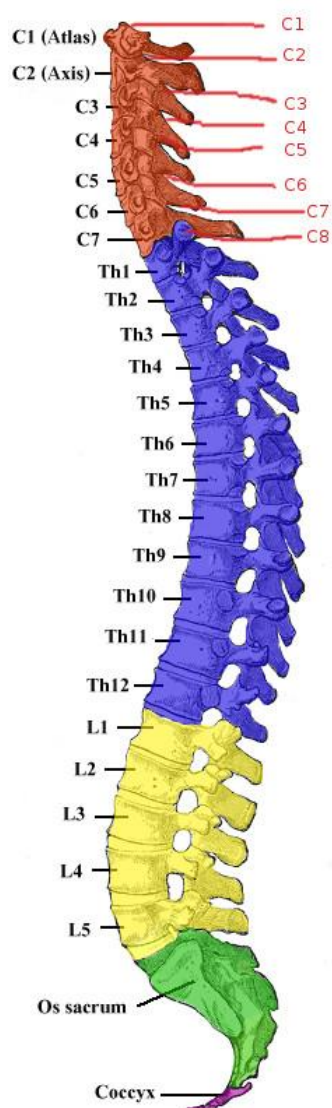


Figure 14. Brachial plexus (Source: Wikipedia.org)

- C5-Th1 (Figure 14)
- **Erb–Duchenne palsy**: upper plexus brachialis impairment (proximal); C5-6; most common; peripheral paresis of delta, biceps and forearm muscles; sensory: radial side of the upper arm and shoulder; commonly traumatic (e.g., injury at birth, motorbike accident, “backpack palsy” – in this case, it can be bilateral). The affected arm is in a slightly inward position and hangs losing its tone. The biceps and radial reflexes are lost.
- **Dejerine-Klumpke palsy**: lower plexus brachialis impairment (distal); C8-Th1; less frequent than the injury of the upper plexus; the wrist and finger flexors, and the small muscles of the hand are mostly affected; sensory: ulnar half of the hand and forearm, always look for symptoms of Horner’s syndrome (e.g., Pancoast tumor, lymphoma infiltration)



Lumbar plexus

- Th12-L4
- genitofemoral nerve, ilioinguinal nerve, femoral nerve, obturator nerve, lateral femoral cutaneous nerve
- Proximal peripheral paresis of the lower limb.
- Injury of the lateral femoral cutaneous nerve (meralgia paresthetica) – pain and numbness on the outer surface of the thigh, which is caused by neuritis, compression under the inguinal ligament, or diabetic polyneuropathy.
- Injury of femoral nerve affects the quadriceps femoris muscle, consequently, the stretching of the knee and flexion of the hip is weakened. It should be distinguished from the L2/L3 or L3/L4 spinal disc herniations.

Sacral plexus

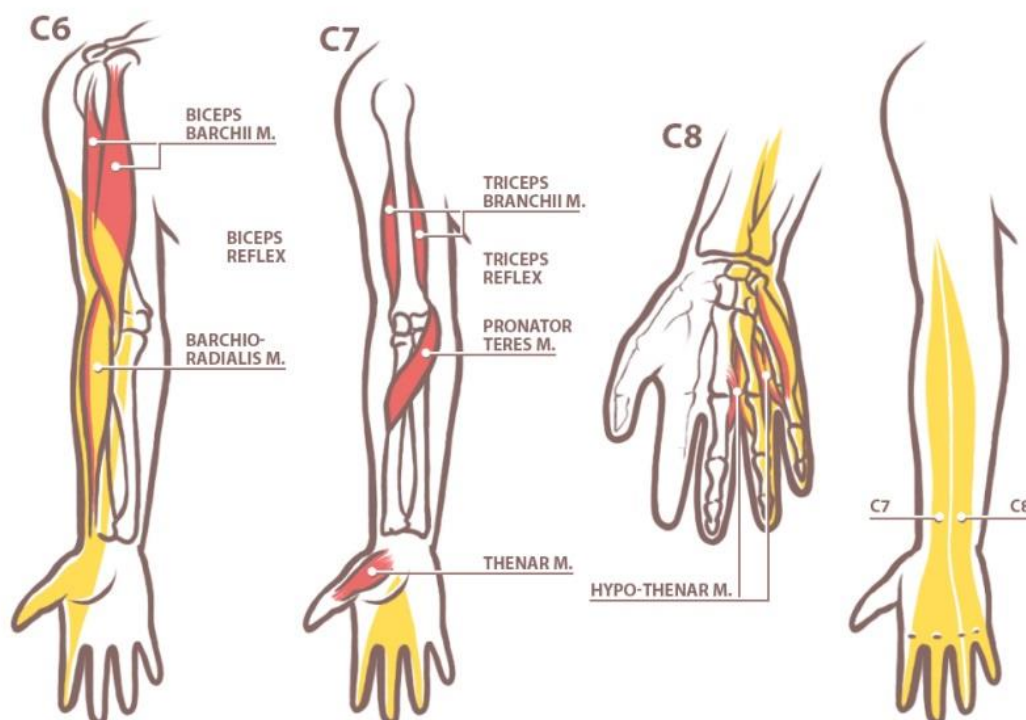
- L4-S4
- superior gluteal nerve, inferior gluteal nerve, ischiadic nerve - common peroneal nerve, tibial nerve
- Distal peripheral paresis and sensory loss of the lower limb.

Root damage

Sensory, motor or vegetative disturbance affecting one root can be observed. Sensory loss affecting one dermatome cannot be observed in all of the cases, because dermatomes often overlap. Humans have altogether 31 of spinal roots. Even though we have 7 cervical vertebrae, 8 cervical spinal root pairs exist (the first spinal roots emerge above the first vertebra, and the eighth spinal pair of roots emerges below the seventh vertebra). The thoracic, lumbar, and sacral nerves are numbered by the vertebra above (Fig. 15.).

Figure 15. The numbering of the vertebrae. The nerve roots emerge below the respective vertebrae (having the same number) except for the cervical nerve roots.

Figure 16. Major root impairments on the upper limb.



C₅ root lesion

Sensory	radiates to the radial part of the upper arm according to the dermatome, but not to the fingers or the lower arm
Motor	the deltoid and biceps brachii muscles are affected
Loss of reflexes	decreased biceps reflex

C₆ root lesion

Sensory	radiates to the radial part of the upper and lower arm, and fingers according to the dermatome
Motor	brachioradialis and biceps brachii muscles
Loss of reflexes	decreased or absent biceps reflex

C₇ root lesion

Sensory	radiates to the middle finger according to the dermatome
Motor	triceps brachii and pronator teres muscles
Loss of reflexes	absent triceps reflex

C₈ root lesion

Sensory	radiates to the little finger according to the dermatome
Motor	hypothenar muscles, weakness, and atrophy of the small muscles of the hand
Loss of reflexes	decreased triceps reflex

L₄ root lesion

Sensory	radiates from the outer side of the thigh through the patella and the inner part of the leg to the inner part of the ankle (but not to the toes) according to the dermatome
Motor	quadriceps femoris and tibialis anterior muscles
Loss of reflexes	absent patella reflex
	Lesions of the femoral nerve and L ₃₋₄ roots can be distinguished by the examination of the thigh adduction. In the femoral nerve lesion, the thigh adduction is sustained, but it is absent in root lesion.

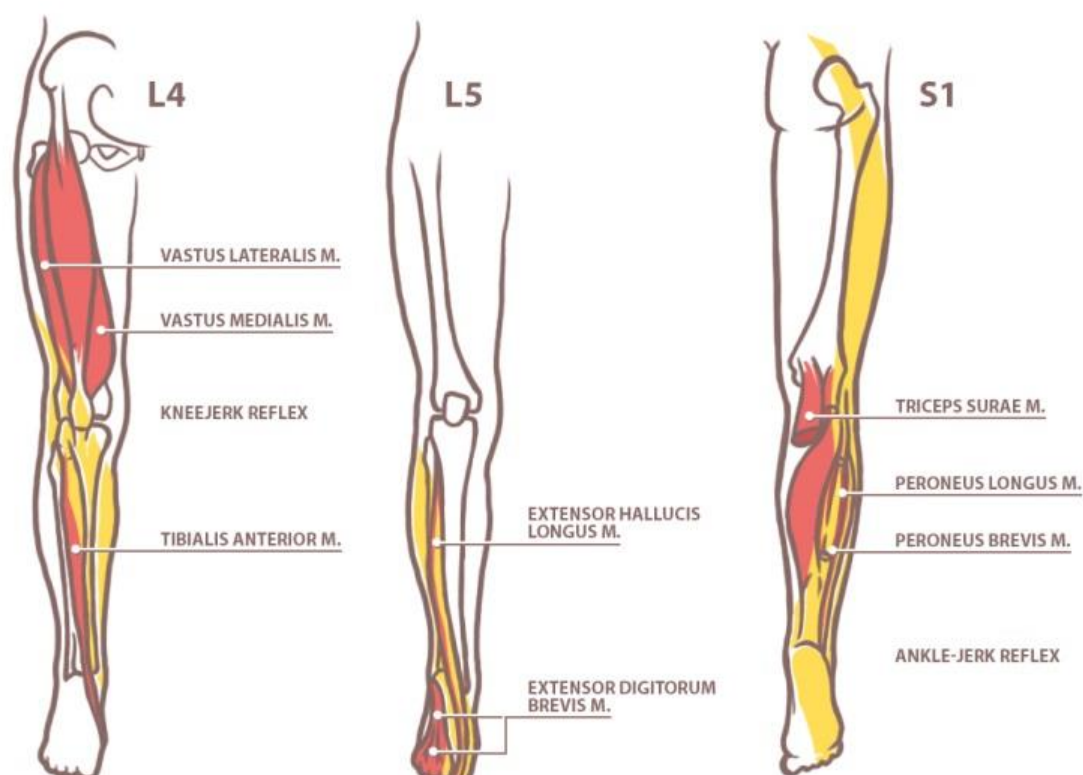
L₅ root lesion

Sensory	it starts above the lateral condyle of the femur and radiates to the hallux at the frontal-external side of the leg according to the dermatome
Motor	extensor hallucis longus muscle
Loss of reflexes	patellar and Achilles reflexes are normal, (only the tibialis posterior reflex is absent)
	In the case of foot drop, lesion of the peroneal nerve and L ₅ root can be distinguished by the examination of the flexion of the toes and extension of the hallux. In the case of injury of the L ₅ root, flexion of the toes (flexor digitorum longus muscle) and extension of the hallux (extensor hallucis longus muscle) are weak; whereas, in the case of injury of peroneal nerve they are normal.

S₁ root-lesion

Sensory	radiates from the bending side of the thigh through the posterior side of the leg to the third, fourth and fifth toes according to the dermatome
Motor	peroneal and triceps surae muscles
Loss of reflexes	absent Achilles reflex

Figure 17. Major root impairments on the lower limb.



Maneuvers for the examination of root injuries

Patrick's test

Patrick's test differentiates the lumbosacral root-lesion and the sacroiliac joint problem. The patient is lying down on his back, flexes the knee of his affected leg and places the heel of the flexed leg on the knee of the other leg. If the pressing down of the leg causes pain in this posture, it refers to sacroiliac joint pain.

Lasègue's sign (straight leg-rising test)

The patient is lying down on his back. Lift one of the lower limbs while the knee is straight.

- **Normally** it is painless.
- **In a positive case**, when the straight leg is at a certain angle, the patient experiences sciatic pain, or pain radiating to the ipsilateral lower limb. It may refer to lumbar or sacral root irritation or compression.
- **Crossed Lasègue's sign.** The pain radiates not only to the ipsilateral limb but also to the contralateral one. It may occur in the case of medial herniation of intervertebral disk.
- In the case of **Kernig's sign**, the pain is accompanied by bending of the knee, and the pain is not radicular.

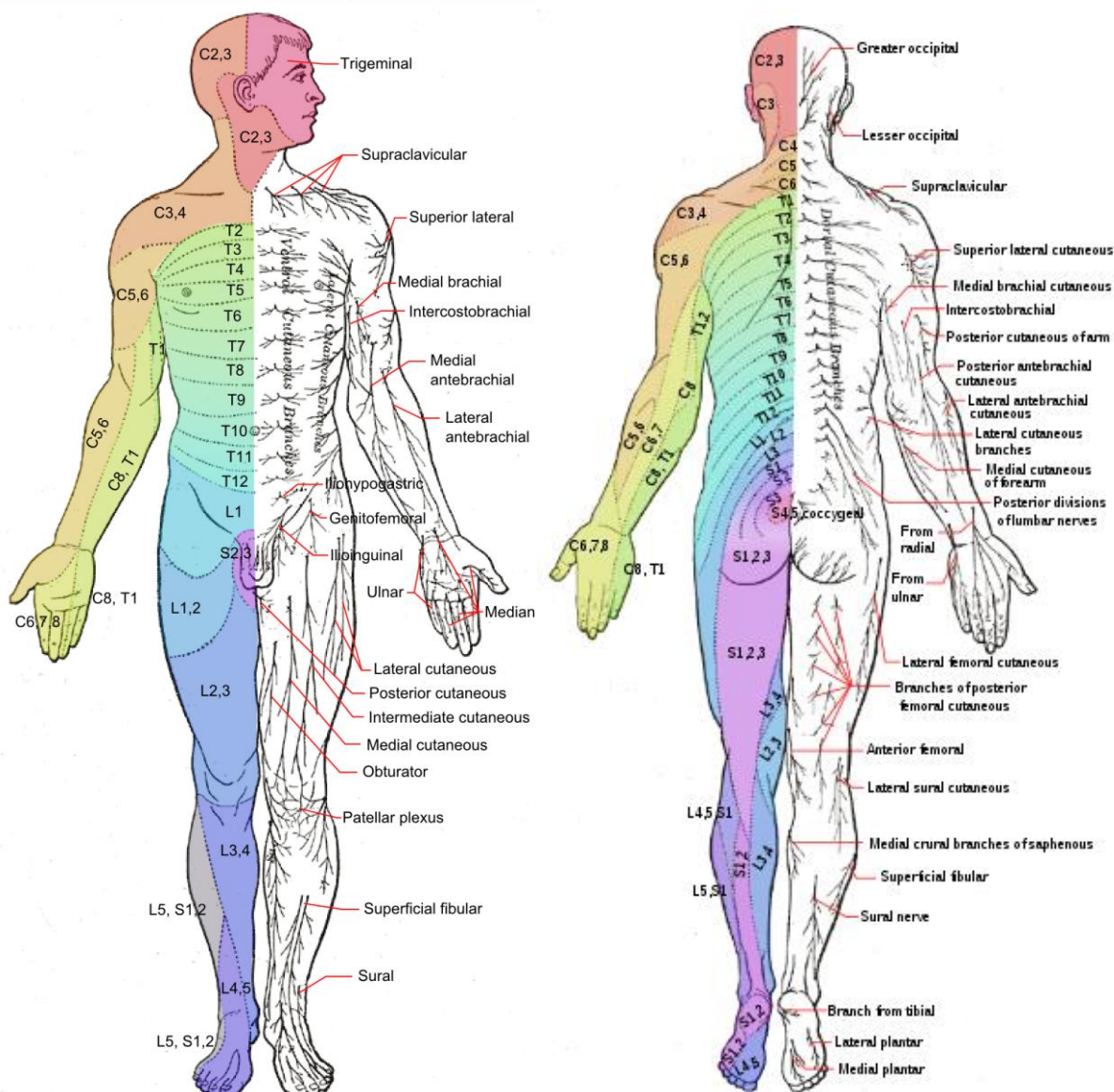


Figure 18. Dermatomes and the main sensory nerves (Source: Wikipedia.org)

Nerve lesion

The sensory, motor or vegetative lesion affects the area of one peripheral nerve territory.

Median nerve

- The most common lesion is the carpal tunnel syndrome

Sensory	the volar aspect of the first, second and third fingers, radial aspect of the fourth finger, and the thenar area are also affected
Motor	thumb opposition, flexion, and abduction, and the flexion of the third and fourth fingers are damaged
Atrophy	thenar muscles
Posture	oath hand (if the ulnar nerve is also affected: ape hand)
Vegetative	complex regional pain syndrome may develop
Special sign	Tinel's sign. The slight pressure on the volar aspect of the wrist causes paraesthesia in the sensory area of the median nerve. It may refer to the presence of carpal tunnel syndrome.

Ulnar nerve

- The most common injury is the elbow tunnel syndrome

Sensory	palmar: ulnar half of 4 th and the whole 5 th finger, dorsal: ulnar half of the 3 rd and the whole 4 th and 5 th fingers (Except for the distal phalanx)
Motor	damaged thumb adduction, Froment's sign, fourth fifth and finger flexion, interosseous muscles
Atrophy	hypothenar and interosseous muscles
Posture	claw hand
Special sign	Froment's sign. Place a piece of paper between the patient's thumb and index finger. Ask the patient to hold the paper, and then try to pull the paper out of his hands. A normal individual will be able to hold the paper without difficulty. In a positive case, the thumb flexes because of the weakness of the adductor pollicis brevis muscle due to injury of the ulnar nerve near the elbow joint, and in this case, the patient will compensate by flexing the FPL (flexor pollicis longus muscle) of the thumb

Radial nerve

- It occurs most commonly in the case of an upper arm break, or injury due to long-term pressure caused by leaning on the upper arm during sleeping on a bench, sometimes in the supinator tunnel

Sensory	the radial dorsal part of the hand
Motor	finger and wrist extensors
Atrophy	finger extensors
Posture	drop hand

Peroneus profundus nerve

Sensory	a small area between the second and third toes
Motor	tibialis anterior muscle (dorsiflexion), toe extensors
Atrophy	tibialis anterior muscle
Posture	foot drop, steppage gait

- The lesion most commonly occurs at the head of the fibula

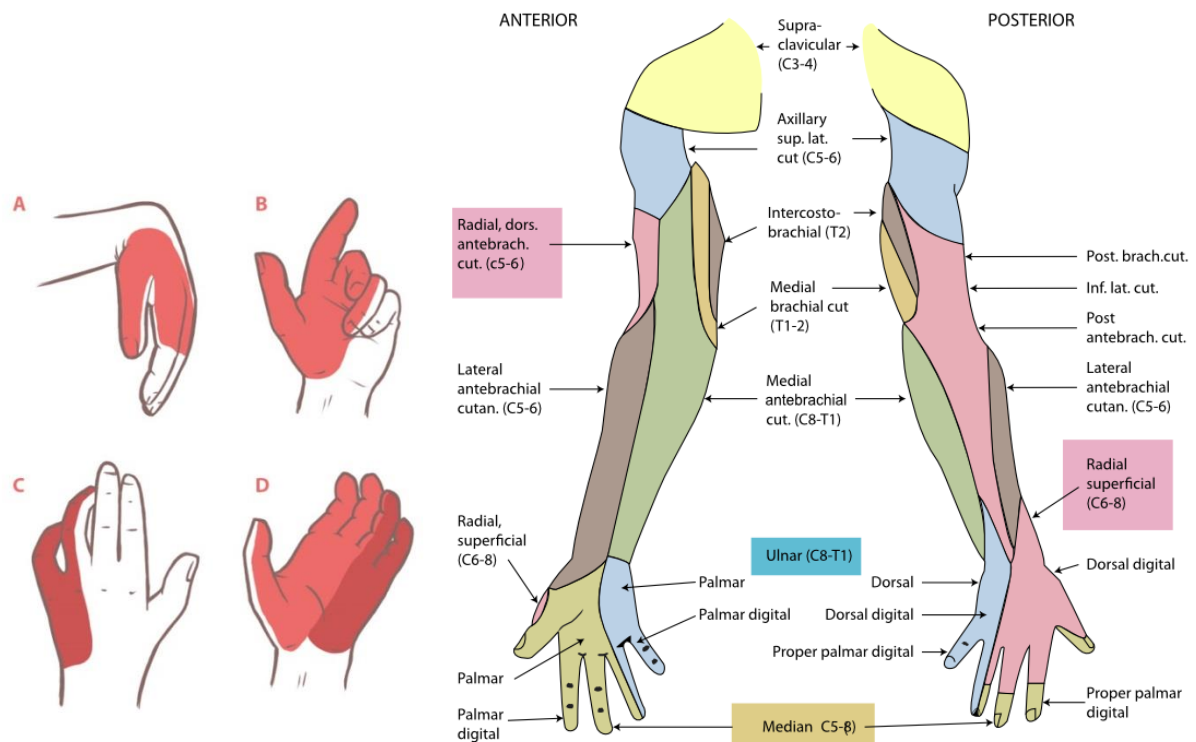


Figure 19. A. radial nerve palsy (drop hand), B. median nerve palsy (oath hand), C. ulnar nerve palsy (claw hand), D. combined median and ulnar nerve lesion (ape hand)

Figure 20. Skin nerves of the upper limb.

Polyneuropathy (PNP)

- Sensory, motor, and vegetative disturbances affecting areas supplied by several nerves
- It is usually more expressed and distal in the lower limbs
- Distal peripheral paresis of the lower limb (e.g., foot dorsiflexion)
- Stocking-glove distribution sensory loss
 - In the case of thick fiber PNP: the vibration quickly cease
 - In the case of small fiber PNP: ENG is negative, only pain appear, vibration sensation may be sustained
 - Usually painful (allodynia)
 - Usually no sensory loss over the trunk and abdomen
- Vegetative disturbance
 - Urination and defecation are sustained
 - Skin ulcers are common

Defect of the neuromuscular junction

- Usually, there is no sensory or vegetative disturbance
- Usually, tetraparesis, which is usually proximal
- Cranial nerve: ptosis with fluctuating severity, eye movement disorder, diplopia, dysarthria, dysphagia
- It may be quickly progressive or suddenly worsening, it is deteriorated by physical exercise, and improved by rest
- Ptosis usually can be provoked

Myopathy

- No sensory or vegetative disturbance
- Usually, tetraparesis, which is usually proximal, but it can also be distal and limb-girdle or faciohumeroscapular as well
- Cranial nerve: ptosis, dysarthria, dysphagia, eye movement disorder (e.g., external ophthalmoplegia)
- The cardiac muscle may also be affected
- Usually, it is slowly progressing

The possible causes of paraparesis

- Spinal lesion: (under Th1)
- Certain brainstem lesions
- Parasagittal processes: e.g., ACA or falx meningioma

Example of a negative status

Skull and spinal cord are intact, with no sign of injury. Neck movements are free, there are no meningeal signs. Accurate vision, the visual field is full. Isocoria, mid-dilated pupils, maintained light reactions. Eye movements are free, with no double vision, no nystagmus. No trigeminal or facial nerve dysfunction. Symmetrical palatal arches, palatal and pharyngeal reflexes, no uvula deviation. The tongue is in the midline, its movements are free. The muscle tone is normal. Muscle trophy is normal. There is no paresis. Mid-brisk, symmetrical deep tendon reflexes. There are no pyramidal signs or pathological reflexes. No sensory loss. Coordination is precise. Normal posture, gait, and speech. Alert and oriented.

References

- Fernandez HH, Eisenschenk S, Yachnis AT, Okun MS.: Ultimate review for the neurology boards. Demos Publishing, New York. 2006. p317-321.
- Baehr M, Frotscher M: Duus' topical diagnosis in neurology. Fourth English Edition. Thieme, Stuttgart. 2005. p. 297-306.
- Mark Edwards, Niall P. Quinn, Kailash Bhatia: Parkinson's Disease and Other Movement Disorders, Oxford University Press, 2008.
- Manji H, Wills A, Kitchen N, Dorwood N, Connolly S, Mehta A: Oxford Handbook of Neurology. Oxford University Press, 2007.

Acknowledgment

I am grateful to Prof. Ferenc Nagy and Dr. Zoltán Pfund for their help in writing this chapter. I am thankful to Dr. Nóra Fehér and Dr. Krisztina Horváth for their constructive comments on my manuscript. I owe special thanks to Dr. Gabriella Gárdián for her revision and remarks. An overview of the causes of cognitive disorders based on the addition of Dr. Béla Faludi.

My work was also supported by the Bolyai János Scholarship of the Hungarian Academy of Sciences.

I would appreciate it if you could send any comments on this booklet to the following email address: kovacsnorbert06@gmail.com.

Index

A

abdominal skin reflex 45
 lower 45
 mid 45
 upper 45
 abducens nerve 20, 70
 absolute pupillary defect 29
 acalculia 63
 accessory nerve 26
 accommodation reflex 16, 29
 Achilles clonus 47, 66
 Achilles reflex 44, 76
 agnosia 63, 70
 tactile 63
 visual 63
 agraphia 63
 akinetic mutism 65
 akinetic-rigid syndrome 53
 alexia 63
 allodynia 49, 50
 alternating brainstem syndromes 11,
 23, 70, 71
 Benedikt's syndrome 70
 Foville's syndrome 70
 Jackson's syndrome 71
 Millard–Gubler's syndrome 70
 Wallenberg's syndrome 71
 alternating cover test 35
 Amaurosis fugax 14
 amusia 63
 anal reflex 46
 analgesia 50
 anamnesis 9
anisocoria 28, 29
 anosmia 12
 anosognosia 63
aphasia 62, 70
 anomic aphasia 62
 Broca's aphasia 62
 global aphasia 62
 jargon aphasia 62
 motor aphasia 62
 nominal aphasia 62
 sensory aphasia 62
 total aphasia 62
 Wernicke's aphasia 62
 aponia 62
 apraxia 61, 70
 constructional apraxia 62
 eyelid-opening 28
 gait apraxia 62
 ideational apraxia 61
 ideomotor apraxia 62
 areflexia 43
 arousal 63
 Astereognosis 63

asterixis 55
 asynergy 57
 ataxia 35, 37, 56, 57, 58, 59, 69, 71
 cerebellar ataxia 56, 57
 sensory ataxia 56, 57, 59
 ataxic gait 59
 athetosis 56
 atrophy 14, 26, 27, 39, 42, 51, 75
 disuse 42
 autotopagnosia 63
 awareness 63

B

Babinski's sign 45, 46, 47, 66
 ballismus 56
 Bárány test 35, 37, 58, 71
 Barre's sign 40
Bell's palsy 19, 22, 23, 24
 Bell's phenomenon 21, 22
 Benedikt's syndrome 70
 benign paroxysmal positional vertigo
 34, 38
 biceps reflex 44
 bidirectional nystagmus 33
 bitemporal (heteronymous)
 hemianopia 14
 bitemporal (heteronymous) upper
 quadrantanopia 14
 blepharospasm 23, 28
 Blind walking test 35, 37, 58
 blink reflex 23, 45
 Brachial plexus 73
 brachioradial reflex 43
 bradykinesia 53, 59
 Brain death 64
 brisk reflex 43, 51
 Brown-Séquard's syndrome 72
 Brudzinski's sign 10
 bulbocavernosus reflex 46
 bulldog reflex 48

C

caloric testing 32, 36
Camptocormia 54
 carpal tunnel syndrome 78
 cauda equina 72
 cavernous sinus 11, 17, 19, 20
 central lesion 11, 51
 central vestibular syndrome 36
 Cervical plexus 73
 Chaddock's sign 47
 Charcot's triad 59
 Cheyne-Stokes breathing 65
 chorda tympani 21, 24
 chorea 56

clonisation 23
 clonus 47
 Achilles 47
 patella 47
 cogwheel phenomenon 42
 Coma 64, 66
 complete ophthalmoplegia 16
 Conductive hearing loss 24
 confusion 65
 conjugate deviation 66
consensual pupillary reflex 29
 Conus 72
 convergence reflex 17, 29, 30
 cornea reflex 19, 20, 23, 45, 64, 66
 cranial nerves 10, 27
 cremaster reflex 46

D

Decerebrate spasticity 41
 decorticate spasticity 41
deep tendon reflexes 51
Dejerine-Klumpke palsy 73
 delirium 65
 diaschisis 39, 52
 diplopia 16, 17, 20, 30, 31, 32, 79
 direct pupillary reflex 15, 29
 Direction changing nystagmus 33
 directional scratch test 50
 dissociated sensory loss 71, 72
 disuse atrophy 42
 Dix-Hallpike maneuver 34
 dizziness 33
 doll's eyes reflex 30, 31, 32, 66
 dysarthria 23, 62, 69, 70, 79, 80
 dysconjugate deviation 66
 dysconjugate eye position 30
 dysdiadochokinesis 59, 71
 dysharmonic vestibular syndrome 36,
 37, 58
 dysmetria 57, 58, 59, 71
 dysphagia 23, 69, 70, 79, 80
 dystonia .9, 23, 27, 28, 42, 53, 55, 56,
 61
 dystrophy 42

E

Edinger–Westphal nucleus 15
En bloc turning 53
 epicritic sensation 48, 72
Erb–Duchenne palsy 73
 external ophthalmoplegia 15
 eye movements
 directed 30
 reflex 30
 spontaneous 30

tracking 30
 eyelid-opening apraxia 28

F

facial asymmetry 23
 facial nerve 15, 19, 20, 22, 23, 45, 70, 80
 facial nerve palsy 21, 22, 23
 central 22
 peripheral 21, 22, 23, 24, 27
 faciobrachial paresis 39
 fasciculation 27, 42
 femoral nerve 74, 76
Festination 53
 Finger-to-nose test 58
 Fissura orbitalis superior syndrome 17, 20
 fixation 30, 34, 36, 57
 flaccid hypotonia 41
 Foville's syndrome 70
Freezing 53
 Frenzel's glasses 34
 Friedreich's ataxia 57
 Froment-manuever 42
Froment's sign 78
 frontal release signs 47
 Fukuda test 35
 Functional blindness 14
 Functional paresis 39, 40
 Functional tremor 59
 fundus 13, 34, 66
 Funicular myelosis 57

G

gait 54, 60
 antalgic 60
 apraxic 61
 blind gait 60
 cerebellar ataxic 61
 dyskinetic 61
 hypokinetic 61
 scissoring 61
 sensory ataxic 61
 spastic 60
 steppage 60
 Trendelenburg 60
 vestibular 61
 waddling 60
 Gasser's ganglion 18
 gaze center 30
 frontal 30, 31
 mesencephalic 30, 31
 occipital 30
 pontine 30, 31
 gaze palsy 30, 31
 horizontal 31
 internuclear 31
 supranuclear 31, 32
 vertical 31
 gegenhalten 42, 48
 genitofemoral nerve 74
 Gerstmann's Syndrome 63
 glabellar reflex 48

Glasgow Coma Scale 66
 glossopharyngeal nerve 25, 26, 45
 Gordon's sign 47
 Gowers' sign 41
 graphesthesia 48, 51
 grasp reflex 48

H

Halmágyi head impulse test 34
 harmonic vestibular syndrome 36, 37
 hearing loss
 conductive 24
 sensoneural 24
 Heel-to-knee-to-shin test 59
 Heel-to-toe test 36, 58
 hemianopia 13
 heteronymous 14, 15
 homonymous 14, 15
 hemiparesis 39, 70, 71
 hemiplegia alternans 11
Hesitation 53
 heteronymous hemianopia 14, 15
 hiccups 55
 hippus 29
 Hoffmann's sign 47
 homonymous hemianopia 14, 15
 homonymous quadrantanopia 14, 15
 homunculus 68, 69
Hoover's sign 39
 Horner's syndrome 28, 29, 66, 73
 hypalgesia 50
 hyperalgesia 50
 hypnoid 64
 hypoglossal nerve 27, 71
 hypokinesia 59
 hypomimia 23
 hyporeflexia 43, 51
 hyposmia 12
 hypotonia 41, 57, 58
 hypotrophy 42, 51

I

inactivity atrophy 42
 increased reflex 43
indirect pupillary reflex 15
 inspection 8
 intention tremor 52, 71
 internal ophthalmoplegia 16
Internuclear ophthalmoplegia 32
 intracranial pressure 13, 17, 20, 31
 ischiadic nerve 74
 isocoria 28, 80

J

Jackson's syndrome 71
 jaw-jerk reflex 19
 Jendrassik-manuever 43

K

Kernig's sign 9, 10, 77
 kinesthesia 50
 kinetic tremor 52
 kinhypesthesia 50

L

lacrimation 21, 23
 Lacunar infarcts 69
lagophthalmos 22, 27
 Lasègue's sign 10, 77
 crossed 77
 latent paresis tests 40, 58
 Barre's sign 40
 Mingazzini's sign 40
 pronator drift sign 40
 lateral femoral cutaneous nerve ... 74
Lhermitte's sign 9
 locked-in syndrome 65
 Lower motor neuron 11, 39
 Lumbar plexus 74

M

mandibular nerve 18, 26, 45
Marcus-Gunn pupil 29
 masseter reflex 18, 19, 43
 maxillary nerve 18
 medial longitudinal fasciculus 30, 32
 Median nerve 78
 meningeal signs 8, 9, 10, 66, 80
 meralgia paresthetica 74
 Millard-Gubler syndrome 23, 70
 Mingazzini's sign 40
 minimally conscious state 65
 monoparesis 39
 monosynaptic reflexes 42
 multiple system atrophy 57
 muscle strength 19, 26, 38, 39, 51, 59
 muscle tone 39, 41, 42, 47, 51, 52, 53, 55
 decerebrate spasticity 41
 decorticate spasticity 41
 flaccid hypotonia 41
 gegenhalten 42
 hypotonia 41
 normotonia 41
 paratonia 42
 rigidity 41
 spasticity 41
 Wernicke-Mann 41
 muscular trophy 19, 38, 42, 51
 atrophy 42
 dystrophy 42
 hypotrophy 42
 inactivity atrophy 42
 normotrophy 42
 mydriasis 28
 Myoclonus 55
 negative 55
 positive 55
 myokymia 42

myopathy..... 80
 myosis..... 15, 28, 29
 myotonia 42

N

neglect..... 63
 hemispatial 63
 sensory 63
 visual 14
 nerve 8, 11, 13, 14, 17, 23, 28, 30, 31,
 45, 49, 60, 70, 71, 72, 73, 74, 76,
 78, 79, 80
 abducens 20
 accessory 26
 facial 15, 20, 23
 glossopharyngeal 25
 greater petrosal 24
 hypoglossal 27
 mandibular 18
 maxillary 18
 median nerve 78
 oculomotor 15
 olfactory..... 11
 ophthalmic..... 18, 19
 optic..... 12, 15
 peroneus nerve..... 78
 radial nerve..... 78
 trigeminal 18
 trochlear 17
 ulnar nerve 78
 vagus..... 25
 vestibulocochlear..... 24
 neuromuscular junction 8, 11, 22, 28,
 31, 39, 51, 79
 normotonia..... 41
 normotrophy 42
 nuchal rigidity 9
 nuclear lesion 11
 Nylen-Bárány test 34
 nystagmus .30, 31, 32, 33, 34, 35, 36,
 37, 38, 57, 58, 59, 61, 70, 71, 80
 acquired..... 33
 bidirectional..... 33
 central..... 33, 36
 congenital 33
 direction changing 33, 37
 gaze-evoked..... 33
 horizontal..... 33
 optokinetic..... 33, 34
 pathological 33
 pendular 33
 peripheral 33, 34, 36
 physiological 33, 34
 provoked..... 33
 rotatory..... 33
 spontaneous 33
 vertical 33

O

occipital nerve 73
 greater 73
 lesser..... 73
 oculocephalic reflex..... 30, 31, 32, 66

oculomotor nerve . 15, 16, 17, 22, 28,
 29, 66, 70
 oculopalpebral reflex... 13, 15, 19, 23
 olfactory nerve..... 11, 12
 ophthalmoplegia
 complete 16
 external..... 15
 internal..... 16
 Oppenheim's sign 47
 optic nerve..... 18, 19, 20, 45
 optic nerve injury 29
 optokinetic nystagmus..... 12, 33, 34
 orofacial dyskinesia..... 23
 Osinski reflex..... 46
 overshoot saccade 31

P

pain sensation..... 18, 19, 20, 50
 pallanesthesia 50
 pallhypesthesia 50
 palmental reflex..... 48
 palpation..... 9, 18, 42, 49, 65
 papillitis..... 13, 14
 papilloedema 13, 14, 66
 paraparesis 39, 71, 80
 parasympathetic fibers 10, 29, 46
 paratonia 42
 paresis..... 38, 39
 faciobrachial paresis 39
 hemiparesis 39
 monoparesis 39
 paraparesis..... 39, 80
 tetraparesis 39
 parkinsonism..... 53, 54, 56, 59
 definition..... 53
 Parkinson-plus syndromes 54
 secondary parkinsonism 54
 parosmia 12
 patella clonus..... 47
 patella reflex..... 44
 Patrick's test 77
 Pendular nystagmus 33
 peripheral lesion ... 11, 19, 26, 34, 51
 peripheral vestibular syndrome..... 36
 Peroneus profundus nerve 78
 persistent vegetative state 65
 pharyngeal reflex .. 25, 26, 27, 45, 64,
 66
 phrenic nerve..... 73
 plantar reflex 45, 46
 plegia 38
 plexus..... 8, 49, 51, 73
 brachial 73
 cervical..... 26, 73
 Lumbar 74
 sacral..... 74
 Polyneuropathy 79
 postural tremor..... 52
 pronator drift sign..... 40
 proprioceptive sensation 18, 48
 prosopagnosia 63
 protopathic sensation 48
 provoked rigidity..... 42

pseudoathetosis..... 56, 59
 pseudobulbar paresis... 23, 26, 27, 70
 ptosis..... 16, 22, 27, 28, 29, 79, 80
 pupil 13, 16, 20, 28, 29, 66
 absolute pupillary defect..... 29
 anisocoria 28
 hippus..... 29
 isocoria 28
 light-refractory 17, 29
 Marcus-Gunn..... 29
 pupillary reflex 15, 16, 29, 64, 66
 consensual..... 29
 direct 15, 29
 indirect 15, 29
 pyramidal signs 38, 39, 43, 46, 51, 52,
 66
 Achilles clonus 47, 66
 Babinski's sign 46
 Chaddock's sign 47
 Gordon's sign..... 47
 Hoffmann's sign 47
 Oppenheim's sign 47
 patella clonus 47
 Schaeffer's sign..... 47
 triflexion response 46
 Trömner's sign 47

Q

quadrantanopia..... 14
 heteronymous 14
 homonymous 14, 15
 Quadriceps clonus 47
 quick alternating movements .53, 59,
 61

R

Radial nerve 78
 radial reflex 43
 Rebound test..... 59, 71
 reflex
 Achilles 44
 biceps 44
 brachioradial 43
 patella 44
 radial 43
 triceps..... 44
 reflex eye movements.. 30, 31, 32, 66
 horizontal 30
 vertical..... 30
 rest tremor 42, 52, 53
 retrobulbar neuritis..... 13, 14
 rigidity 9, 41, 53, 54
 Rinne test 24
 Romberg test..... 35, 37, 57, 58, 71

S

saccade..... 31, 34, 35, 58
 overshoot 31
 undershoot..... 31
 Sacral plexus..... 74
 saliva secretion..... 21, 25

scanning dysarthria	58, 71
Scanning speech	58
Schaeffer's sign	47
Sensoneural hearing loss	24
sensory system	48
directional scratch	50
fine touch	49
graphesthesia	51
joint position	50
pain	50
simultaneous double stimuli	51
temperature	50
two point discrimination	51
vibration	50
Sharpened Romberg test	35
simultaneous double stimuli	51
skew deviation	30, 35, 37, 38, 66, 70
smooth pursuit	30
soft palate reflex	25, 26, 45, 66
Somnolence	64
Sopor	64
spasticity	41, 47
decerebrate	41, 66
decorticate	41, 66
Wernicke-Mann	41
spinocerebellar ataxia	57
square wave jerks	30, 57
stapedius reflex	20, 23
sternocleidomastoid muscle	26, 27
strabismus	30, 36
straight leg-rising test	77
superficial reflexes	19, 45, 64
abdominal skin reflex	45
anal reflex	46
blink reflex	45
bulbocavernosus reflex	46
cornea reflex	19, 23, 45
cremaster reflex	46
pharyngeal reflex	25, 26, 27, 45, 64
plantar reflex	45
soft palate reflex	25, 26, 45
supranuclear lesion	11, 22
sympathetic fibers	10, 28, 29, 71
synkinesis	23, 54, 60, 61

T

Tabes dorsalis	57
tactile anesthesia	49
tactile hypesthesia	49
Tandem gait test	36, 58
task specific tremor	53
tenebrosity	64
tentorial herniation	17, 28, 29, 66
tetraparesis	39, 71, 79, 80
thermoanesthesia	51
thermohyperesthesia	51
thermohypesthesia	51
tic 23, 54	
Complex motor tic	54
Complex vocal tic	54
Simple vocal tic	54
Simplex motor tic	54
Tinel's sign	78
Tolosa-Hunt syndrome	17
tongue tremor	27
Torpidity	64
tracking eye movements	30
trapezius muscle	26
tremor	52, 53, 57
cerebellar tremor	52, 58
intention tremor	52, 58
kinetic tremor	52
postural tremor	52
rest tremor	52
task specific tremor	53
triceps reflex	44
triflexion response	46, 47
trigeminal ganglion	18
trigeminal nerve	12, 18, 20, 26, 45
trigeminal neuralgia	18
trochlear nerve	17
Trömner's sign	47
two-point discrimination	18, 48, 51

U

ulnar nerve	78
undershoot saccade	31
upper motor neuron lesion	26, 39
Uterberger test	35
uvula	25, 45, 80

V

vagus nerve	25, 26, 45
vertigo	24, 31, 33, 37, 58
vestibular neuronitis	37
vestibular syndrome	
central	36
dysharmonic	36, 37
harmonic	36, 37
peripheral	36
vestibulocochlear nerve	23, 24, 34
vestibuloocular reflex	32, 64
vigilance	64
visual acuity	12, 13
visual agnosia	63
visual field . 13, 14, 15, 19, 23, 31, 69, 80	
nasal	13
temporal	13
visual inattention	14
visual neglect	14
vocal cord palsy	25

W

Wallenberg syndrome	71
watershed (borderzone) infarcts ..	70
Weber's test	24
Wernicke-Mann spasticity	41

A

α -motor neuron	18, 39, 43
------------------------------	------------